Ortho.Lec.2 2019/2020 5th class Lecturer Zainab Bahgat

INTRA-ORAL EXAMINATION

- **EXAMINATION OF TONGUE :-**

- Abnormalities of the tongue can upset the muscle balance and equilibrium leading to malocclusion.
- Presence of excessively large tongue is indicated by scalloping on the lateral margins of the tongue.
- The lingual frenum should be examined for tongue –tie as it alters the resting tongue position and impairs the tongue movement.

▶ Examination of the palate :- The palate should be examined for the following findings :

- Variation in palatal depth
- Presence of swelling
- Presence of clefts

- **EXAMINATION OF GINGIVA** :-

- The gingiva should be examined for inflammation, recession and other mucogingival lesions.
- Presence of poor oral hygiene is usually associated with generalized marginal gingivitis.
- Anterior marginal gingivitis can be seen in mouth breathers due to dryness of the mouth .
- Bleeding on probing may indicates active disease, which must be brought under control before treatment is undertaken.

- **EXAMINATION OF FRENAL ATTACHMENTS :-**

- A heavy maxillary labial frenum may be cause of a midline diastema.
- Abnormal frenal attachments are diagnosed by a blanch test where the upper lip is stretched upwards and outwards for a period of time.

Assessment of the dentition :- The dentition is examined and the following details are recorded :

- Status of dentition i.e. erupted and missing teeth.

Presence of caries, restorations, malformations, hypoplasia, wear and discoloration.

- **Antero – posterior relation** :

  - Angle's class I (neutrocclusion, normal antero-posterior relationship)
  - Angle's class II div. 1 (distoclusion with labioversion of the maxillary incisors)
  - Angle's class II div. 2 (distoclusion with linguo-version of the upper incisors)
  - Angle's class III (mesioclusion)

- Over jet and overbite
- Transverse malrelations, like cross bite and shift of midline
- Individual tooth irregularities such as rotations, displacements, intrusion and extrusion
- Arch form and symmetry.

Functional examination :-

- Improper functioning of the stomatognathic system can result in various malocclusions.
- The functional examination should include :

a. Assessment of postural rest position and inter occlusal space

b. Path of closure

c. Assessment of respiration

d. Examination of TMJ

e. Examination of swallowing

f. Examination of speech

Assessment of postural rest position and inter – occlusal clearance :-

- The postural rest position is the position of the mandible at which the muscles that close the jaws and those that open them are, in a state of minimal contraction to maintain the posture of the mandible.
- At the postural rest position, a space exist between the upper and lower jaws. This space is called the inter occlusal clearance or the freeway space.
- Normally the freeway space is 3mm in canine region.

EVALUVATION OF PATH OF CLOSURE

The path of closure is the movement of mandible from the rest position to habitual occlusion .

- ***Forward path of closure:*** a forward path of closure occurs in patients with a skeletal Class II relationship and an underlying skeletal Class II jaw relationship will position the mandible forward in a "Sunday bite," making the occlusion look better than it really is.
- Sometimes an apparent Class III relationship results from a forward shift to escape incisor interferences in what is really an end-to-end relationship. These patients are said to have pseudo-Class III malocclusion
- ***Backward path of closure:*** class 11 ,division 2 exhibit premature incisor contact due to retroclined maxillary incisors. Thus the mandible is guided posteriorly to establish occlusion
- ***Lateral path of closure :*** lateral deviation of mandible to left or right side is associated with occlusal prematurities and a narrow maxillary arch

A child with an apparent unilateral crossbite usually has a bilateral narrowing of the maxillary arch, with a shift to the unilateral crossbite position. It is vitally important to verify this during the clinical examination, or to rule out a shift and confirm a true unilateral crossbite

ASSESSMENT OF RESPIRATION

Humans may exhibit three types of breathing: nasal ,oral and oro-nasal

Test to diagnose the mode of respiration:

- ***Mirror test :*** a double sided mirror is held between the nose and the mouth .fogging on the nasal side of the mirror indicates nasal breathing while fogging towards oral side indicates oral breathing
- ***Cotton test :*** a butterfly shaped cotton piece is placed over the upper lip below the the nostrils . if the cotton flutters down indicates nasal breathing .this test is used to determine the unilateral nasal blockage
- ***Water test:*** the patient is asked to fill his mouth with water and retain it for a long period of time .while nasal breathers accomplish this with ease , mouth breathers find it difficult task.
- ***Observation*** : in nasal breathers the external nares dilate during inspiration .in mouth breathers ,there is either no change in the external nares or they may constrict during inspiration

EXAMINATION OF T.M.J.

The functional examination should routinely include auscultation and palpation of temporomandibular joint and musculature associated with mandibular opening.

The patient should be examined for the symptoms of temperomandibular joint problems like clicking, crepitus , pain of masticatory muscles ,limitation of jaw movement , hyper-mobility and morphological abnormalities.

The maximum mouth opening is determined by measuring the distance between the maxillary and mandibular incisal edges with mouth wide open. The normal inter incisal distance is 40- 45 mm

EVALUVATION OF SWALLOWING

In a new born, tongue is relatively large and protrudes between the gumpads and takes part in establishing the lip seal .this kind of swallow is called infantile swallow and is seen till one and half to two years of age .

Infantile swallow is replaced by mature swallow as the buccal teeth start erupting. The persistence of infantile swallowing can cause malocclusion .thus the swallowing pattern of the individual should be examined.

The persistence of the infantile swallow is indicated by the presence of the following features:

a. Protrusion of the tip of tongue

b. Contraction of perioral muscles during swallowing

c. No contact at the molar region during swallowing

SPEECH

Certain malocclusions may cause defects in speech due to interference with the movement of tongue and lips .this should be observed while talking with the patient .

The patient can be asked to read out from a book or asked to count from 1-20 while observing the speech.

Patients having tongue thrust habit tend to lisp while cleft palate patients may have a nasal tone

Facial photographs :-

Facial photographs offer a lot of information on the soft tissue morphology and facial expression.

▶ **The extra oral photographs** :-

These are taken by positioning the patient in such a manner that the F – H plane is parallel to the floor. Frontal view, Profile view , Oblique view

▶ The intra oral photographs :-

USES OF PHOTOGRAPHS

1. Useful in assessment of facial symmetry ,facial type and profile
2. Serve as a diagnostic records
3. Help in assessing the progress of the treatment

RADIOGRAPHS USED IN ORTHODONTIC DIAGNOSIS

- **Radiograph routinely used for diagnosis in orthodontic s are classified into two groups**

1. **Intra-oral radiograph**
2. **Extra-oral radiograph**

Intra –oral periapical radiographs(I.O.P.A)

- They are radiographs that are used to view the teeth and their supporting structures. **USES**
- To confirm presence or absence of teeth
- To establish presence or absence of supernumerary teeth
- Extent of calcification and root formation of teeth
- To study alveolar bone & PDL
- To determine size and shape of unerupted teeth
- To assess axial inclination of roots

Disadvantages

- Assessment of entire dentition requires too many radiographs.
- They cannot be used in patients with high gag reflex and trismus

Advantages

- Low radiation dose
- Excellent clarity of teeth and their supporting structure
- Possible to obtain localized view of area of interest.

BITEWING RADIOGRAPHS

- ▶ It records the coronal part of upper and lower dentition along with their supporting structure.

1. Used to detect proximal caries
2. Height and contour of inter alveolar bone
3. To detect periodontal changes
4. To detect secondary caries below restorations.
5. To determine inter proximal calculus

OCCLUSAL RADIOGRAPHS

- ▶ Occlusal radiographs are used in patients who are unable to open their mouth wide enough for periapical radiographs.

Uses

1. To locate impacted or unerupted teeth
2. To locate supernumerary teeth
3. To locate foreign bodies in the jaw
4. To diagnose the presence and extend of fractures

EXTRA-ORAL RADIOGRAPHS

- THEY ARE USEFUL WHEN LARGE AREAS OF FACE AND SKULL ARE TO BE VISUALIZED

PANORAMIC RADIOGRAPH

- ▶ It enables viewing of both maxillary and mandibular arches with their supporting structures

USES:

- ▶ Studying deciduous root resorption and root development of permanent teeth
- ▶ To study the path of eruption of the teeth

- Used to view ankylosed and impacted teeth
- To diagnose presence and extend of pathology and fractures of jaw

ADVANTAGES

- Broad anatomic area can be visualized
- Radiation exposure is low
- Can be used in patient who are unable to tolerate intra oral films or unable to open the mouth

DISADVANTAGES

- Expensive equipment
- Inclination of anterior teeth cannot be visualized
- Less clear images as in periapical films
- Distortion, magnification and overlapping of the structures occur

CEPHALOMETRIC RADIOGRAPHS

- Specialized skull radiograph in which the head is positioned in a specially designed head holder cephalostat.
- It is of two types

1. Lateral cephalogram
2. Postero-anterior cephalogram

HAND-WRIST RADIOGRAPH

Radiograph of hand and wrist are useful in estimating the skeletal age of a person .the hand and wrist region have number of small bones whose appearance and progress of ossification occur in a predictable sequence. This enables skeletal age of a person they are useful in assessing growth for planning growth modification procedures and surgical resective procedures

Refrences

-An Introduction to Orthodontic.fourth edition 2013 United Kingdom--Laura Mitchell, MBE Oxford

-CONTEMPORARY ORTHODONTICS , FifTH EDITION 2013--WILLIAM R. PROFFIT, MOSBY

--Textbook of Orthodontics Second Edition: 2007--Gurkeerat Singh, Jaypee New Delhi 110 002, India

--ORTHODONTIC REVIEW, SECOND EDITION 2015--Jeryl D. Sercan Akyalcin -Timo Peltomäki -Kate Litschel, by Mosby, an imprint of Elsevier Inc

Ortho.Lec3 2019/2020 5th class Lecturer Zainab Bahgat

DEFINITION OF CROSSBITE

According to ***Graber:***

A condition where one or more teeth may be malposed abnormally-buccally , labially or lingually with refernce to opposing tooth or teeth.

OR

-A deviation of the normal faciolingual relationship of teeth of one arch with those of opposing arch when the two dental arches are brought into centric occlusion

Other definition

- -Abnormal occlusion in the transverse plane
- OR
- -Reverse overjet of one or more teeth
- -a discrepancy in the buccolingual relationship of the upper and lower teeth.
- Under **normal** circumstances- maxillary arch overlaps mandibular arch both labially and buccally.
- But when mandibular teeth (single tooth or a segment of teeth) overlap maxillary teeth labially or buccally depending upon their location in the arch a **crossbite** is said to exist

CLASSIFICATION OF CROSSBITES



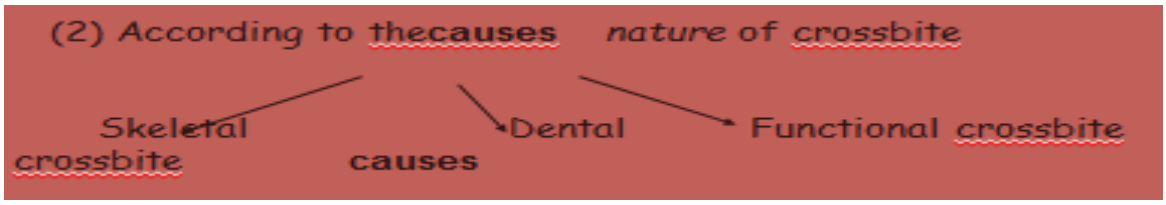

- Based on the structure involved:

- **Dental crossbite:** crossbite is confined to the dentition, mainly lingual tipping of upper teeth or less frequently buccal tipping of lower teeth.
- **skeletal crossbite:** crossbite involving the skeletal structures mainly maxillary constriction.
- **Functional crossbite:** Occlusal interference will lead to mandibular shift on closure resulting in anterior or unilateral posterior crossbite

Anterior cross bite

Single tooth anterior cross bite

Segmental anterior cross bite

- **The Simple Anterior Crossbite**
- **The Functional Anterior Crossbite**

  (pseudo Class III)
- **The Skeletal Anterior Crossbite**

Simple anterior crossbites are generally the result of an abnormal eruption of the permanent incisors.

The term simple is used because these crossbites can easily be corrected using removable appliances by practitioners with limited experience in orthodontics

Various etiologic factors can be involved including

- trauma to the primary incisors with displacement of the permanent tooth bud;
- delayed exfoliation of a primary incisor with palatal deflection of the erupting permanent incisor;
- supernumerary anterior teeth; odontomas;
- congenitally abnormal eruption patterns ,
- and an arch perimeter deficiency

Patients who have a simple anterior dental crossbite exhibit the following characteristics

- a. The crossbite usually involves only one or two teeth.
- b. The facial profile is usually normal in centric relation and centric occlusion.
- Many of these patients exhibit Class I skeletal patterns.
- d. There is usually no shift from rest to intercuspation, as the teeth involved in the crossbite have moved to accomodate the interference.

Functional cross bites

- These cross bites are usually caused due to the presence of occlusal interferences during the act of bringing the jaws into occlusion result in deviation of mandible into an abnormal but often a more comfortable position.
- These can be caused by the early loss of deciduous teeth, decayed teeth or ectopically erupting teeth.
- If not corrected early, these can ultimately lead to skeletal cross bites.

The Skeletal Anterior Crossbite

1.Anterior cross bite due to maxillary retrognathism

2.Anterior cross bite due to mandibular prognathism

3.Anterior cross bite due to maxillary retrognathism and mandibular prognathism

Its characteristics

a. In centric occlusion their facial profile will be straight or concave.

b. There will be a Class III molar relationship and an anterior crossbite.

c. The arc of mandibular closure remains smooth without any occlusal interferences

d. In an attempt to compensate for the skeletal discrepancy during growth, the maxillary incisors usually become proclined and the mandibular incisors become retroclined

Anterior crossbite may lead to:

- ❖ tooth attrition,
- ❖ gum recession and periodontal pockets,
- ❖ and most dangerously mandibular displacement, mostly the forward postural type which may mask the increase in overjet in the central incisor area.
- ❖ may lead to temporomandibular disorder

Classification ❖

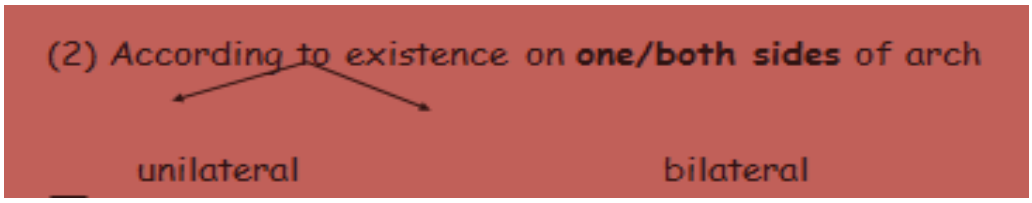



(3) **Classification** Based on **the position of upper molars**:

- **Palatal Posterior Crossbite:** is the most common and refers to a condition where buccal cusps of one or more maxillary posterior teeth occlude lingual to buccal cusps of mandibular teeth.
- **Buccal Crossbite (Scissors Bite):** the palatal cusps of maxillary teeth occlude buccal to mandibular teeth. This type is less common and associated with underlying skeletal discrepancy, often Class II malocclusion

skeletal posterior crossbite

- It results from discrepancy in **structure** of maxilla and mandible

  or ***– malposition of the jaw***.

- A basic discrepancy in the **width of arches** is noted.

- A narrow maxillary arch or a wide mandibular arch often

  assosciated with a posterior crossbite.

Generally, the greater the number of teeth in crossbite, the greater is the skeletal component of the aetiology

- For this reason palatal crossbites of an entire buccal segment are most commonly associated with Class III malocclusions,
- and Scissors bite crossbites are associated with Class II malocclusions.
- Anterior crossbites are associated with Class III skeletal patterns

Displacement: on closing from the rest position the mandible encounters a deflecting contact(s) and is displaced to the left or the right, and/or anteriorly, into maximum interdigitation

Diagnosis

- ✓ **Clinical Examination:**

It is important to determine whether a unilateral crossbite is associated with lateral mandibular shift, this is achieved by examining mandibular position in centric relation and centric occlusion.

Unilateral posterior crossbite with lateral shift may result from:-

1. **<u>Occlusal interferences from primary canine</u>: there is normal occlusal relations at initial contact but in centric occlusion there is mandibular shift leading to unilateral crossbite.**
2. **Or** the underlying aetiology is usually that the maxillary arch is of a similar width to the mandibular arch (i.e. it is too narrow) with the result that on closure from the rest position the buccal segment teeth meet cusp to cusp. In order to achieve a more comfortable and efficient intercuspation, the patient displaces their mandible to the left or right

- ✓ **Marked bilateral narrowing produce no interference and the patient will have bilateral crossbite in centric relation.**
- ✓ **Less frequently unilateral posterior crossbite is caused by true unilateral narrowing of the upper arch, the patient has crossbite in centric relation and centric occlusion.**
- ✓ **Study cast analysis:**

dental and skeletal transverse dimensions can be recorded using study cast by:

- **Measuring the width of palatal vault.**
- **Measuring the intermolar distance.**

These 2 measurements should be compared to each other to verify the skeletal and dental contribution to crossbite.

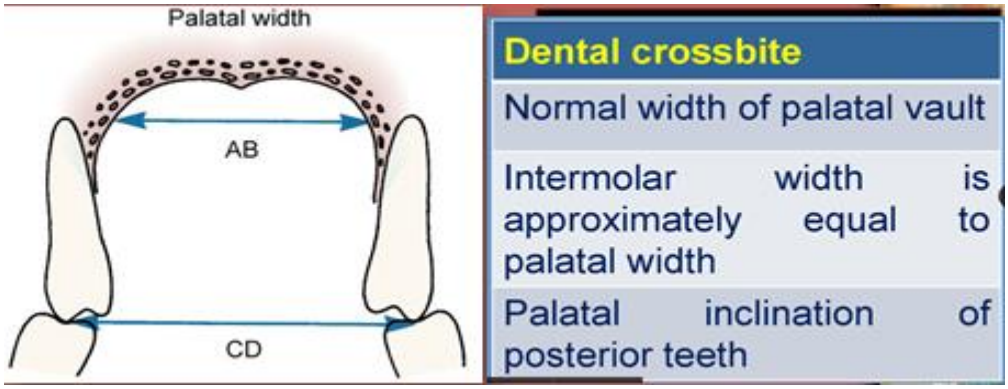

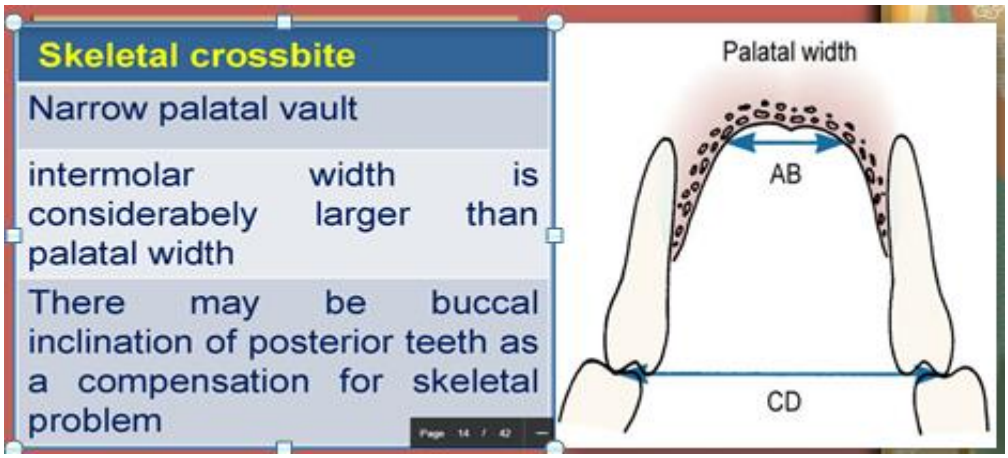

- ☑ **In normal occlusion the arch width between tips of MB cusps of upper first molars should be 2 mm greater than the width between buccal grooves of lower molars.**
- ☑ **Arch width measurement is used to estimate the amount of expansion needed to correct the crossbite:**
- ➢ **maxillary intermolar width – mandibular intermolar width= intermolar difference.**
- ➢ **expansion needed= intermolar difference +2mm.**

Etiology of skeletal crossbites

1) Anteroposterior skeletal problem, sever maxillary retrognathism or mandibular prognathism can result in posterior crossbite even with normal transverse maxillary width.

2) Narrow upper arch.

3) Unilateral hypo/hyperplastic growth of any jaw.

4) Hereditary (Class III skeletal malocclussion).

5) Congenital (Cleft lip and palate).

6) Trauma at birth (forcep injury leading to ankylosis of TMJ.)

7) Trauma during growth (ankylosis of TMJ and retardation of growth in traumatized bone).

8) ***Habits*** such as prolonged thumb sucking and mouth breathing. Because they cause *lowered tongue* position ,thus tongue no longer balances the forces exerted by the buccal group of musculature, which leads to narrowing of upper arch leading to posterior crossbite.

Etiology of dental crossbite are **:-**

1) Anomalies in tooth number (supernumerary teeth)

2) Anomalies in tooth size macrodontia

4) Premature loss of deciduous

5) Prolonged retention of deciduous teeth

6) Delayed eruption of permanent teeth

7) Abnormal eruption path

8) Ankylosis

Rarer causes

- These include cleft lip and palate, where growth in the width of the upper arch is restrained by the scar tissue of the cleft repair. Trauma to, or pathology of, the temporomandibular joints can lead to restriction of growth of the mandible on one side, leading to asymmetry

Refrences

-An Introduction to Orthodontic.fourth edition 2013 United Kingdom--Laura Mitchell, MBE Oxford

-CONTEMPORARY ORTHODONTICS , FifTH EDITION 2013--WILLIAM R. PROFFIT, MOSBY

--Textbook of Orthodontics Second Edition: 2007--Gurkeerat Singh, Jaypee New Delhi 110 002, India

--ORTHODONTIC REVIEW, SECOND EDITION 2015--Jeryl D. Sercan Akyalcin -Timo Peltomäki -Kate Litschel, by Mosby, an imprint of Elsevier Inc

Ass. Prof. Zena Hekmat

ORAL HABITS

Is the action which by repetition become spontaneous

Oral habits are:-

- Thumb sucking.
- Tongue thrusting.
- Mouth breathing
- Bruxism
- Nail biting
- Lip biting.

Thumb & Finger Habits

About two thirds are ended by 5 years of age. The types of dental changes that a digit habit may cause vary with the intensity, duration, and frequency of the habit as well as the manner in which the digit is positioned in the mouth.

-Intensity is the amount of force that is applied to the teeth during sucking.

-Duration is defined as the amount of time spent sucking a digit

-Frequency is the number of times the habit is practiced throughout the day

The most common dental signs of an active habit are reported to be the following:

-Anterior open bite

-Facial movement of the upper incisors and lingual movement of the lower incisors. The result is an increased overjet and, by virtue of the tipping, decreased overbite

-Lips:-Upper lip may be short and hypotonic

Lower lip is hyperactive

-Maxillary constriction (decreased hard palate width) with can result in posterior crossbite.

Extraoral Examination :-(i) The digits:-Digits that are involved in the habit will appear reddened, exceptionally clean, chapped & short fingernail (dishpan thumb)Fibrous roughened callus may be present on superior aspect of finger.

Treatment of Thumb & Finger Habits

-At first consultation with his family and with him.

-The second approach, reminder therapy, is appropriate for those who desire to stop the habit but need some help.

-An adhesive bandage secured with waterproof tape on the offending finger can serve as a constant reminder.

-Another approach is to paint a commercially available bitter substance on the fingers that are sucked.

-The two appliances used most often to discourage the sucking habit are the quad helix and the palatal crib

The quad helix is a fixed appliance commonly used to expand a constricted maxillary arch –a common finding accompanied by posterior crossbite in NNS patients.

The palatal crib is designed to interrupt a digit habit by interfering with finger placement and sucking satisfaction.

The palatal crib is generally used in children in whom no posterior crossbite exists.

It may, however, also be used as a retainer after maxillary expansion with a quad helix in a child who has not stopped sucking with quad helix.

For a palatal crib, bands are fitted on the permanent first molars or primary second molars. A heavy lingual arch wire (38 mil) is bent to fit passively in the palate and is soldered to the molars bands.
The parent and child should be informed that certain side effects appear temporarily after the palatal crib is cemented.

Eating, speaking, and sleeping patterns may be altered during the first few days after appliance delivery, these difficulties usually subside within 3 days to 2 weeks. An imprint of the appliance usually appears on the tongue as an indentation .

Habit discouragement appliances should be left in the mouth for 6 to 12 months as a retainer.

The palatal crib usually stops sucking immediately least another 6 months of wear to extinguish the habit completely.

The quad helix also requires a minimum of 6 months of the treatment. Three months are needed to correct the crossbite, and 3 months are required to stabilize the movement.

Pacifier Habits

Dental changes created by pacifier habits are largely similar to changes created by thumb habits, and no clear consensus indicates a therapeutic difference.

Anterior open bite and maxillary constriction occur consistently in children who suck pacifiers.

Pacifier habits appear to end earlier than digit habits


<u>Lip Habit</u>
Habit that involve manipulation of the lips and perioral structures

LIP appearance

Red, inflamed, and chapped lips and perioral tissue during cool weather. The result is a proclination of the maxillary incisors, a retroclination of the mandibular incisors, and an increased amount of overjet.
TREATMENT
By the orthodontic appliance like lip bumper &oral screen and treat the malocclusion

<u>Tongue thrusting</u>
Definition:-¬ The forward movement of tongue tip between the teeth to meet the lower lip during deglutition and in sounds speech so that tongue becomes interdental

Clinical features :
- Extra oral
(1) Lip Posture :- Lip separation is more both at rest & in function
(2) Mandibular movement :- Path of mandible movement is upward & backward with tongue movement forward.
(3) Speech : Lipsing problem in articulation of s/n/t/d/ l/th/z/v/ sounds.

(a) Facial form :- increase anterior facial height

- Intraoral

(1) Tongue posture:-Tongue tip at rest is lower because of anterior open bite present

(2) Tongue movement :- Movement is irregular from one swallow to another.

- Malocclusion:-

In maxilla Proclination of maxillary anterior .

¬ An increase over jet

¬ Maxillary constriction

¬ Generalized spacing between teeth.

In Mandible :- Retroclination of mandibleDiagnosis

Management:-It is aimed at teaching the child correct positioning of tongue

1) Patient is instructed to put the tip of tongue at correct positions and swallow with Lip pursed and teeth in occlusion

.2) Training to correct swallow and posture of tongue.

3) Flat sugarless fruit drop can be placed on back of the tongue & it is held against the palate in the correct position until it is completely dissolving twice a day.

4) When patient learn normal tongue position this has to be reinforced and made into on unconscious act.

5) Appliance therapy used can be either fixed with band palatal rake or removable with adam's clasp.

6) Nance Palatal Arch Appliance – in this acrylic button can be used as to guide the tongue in right position.

7) Removable appliance therapy

8) Fixed Habit breaking Appliance

Mouth breathing habits

 Definition:- Sassouni (1971) Mouth breathing as habitual respiration through the mouth instead of the nose.

 Etiology:- It is estimated that 85% mouth breather suffer from some degree of nasal obstruction

1. Developmental Anomalies like abnormal development of nasal cavities .

2. Partial obstruction in deviated nasal septum and Localized benign tumor.

3. Infection inflammation of nasal mucosa as:- Chronic allergic, chronic atrophic Rhinitis, Enlarged adenoid tonsils

(4) Traumatic injures of nasal cavity

(5) Genetic Pattern

Clinical Features: -

Facial appearance of child with mouth breathing habit is termed as Adenoid facies.

Long narrow face.

narrow nose and nasal passage.

Short upper lip.

Nose tipped superiorly

Expressionless face.

θ Dental effect (intra oral)

Protusion of maxillary incisors

Palatal vault is high.

Increase incidence of caries.

Chronic marginal gingivitis.

Diagnosis :-

(1) History:- The parents can be questioned whether the child adopts frequent lip apart posture&Frequently occurrences of tonsillitis, allergic rhinitis.

(2) Examination:-

(i) Observe the patient unknowingly while at rest in a nasal breather

– lip touch lightly in mouth breather

– Lip are kept apart.

(ii) Patient asked to take deep breath Nasal breather keep the lip tightly closed Mouth breather take deep breath keeping mouth open.

(iii)Clinical test: -

(a) Mirror test:- Double side mirror is held b/w the nose and mouth fogging on the nasal side of mirror indicate nasal breathing while fogging toward the oral side indicate oral breathing.

(b) Water test:- The patient is asked to fill the mouth with water, and hold it for a period of time. While nasal breather accomplishes with ease, mouth breather find the task difficult.

(c) Cotton test:- A butterfly shaped piece of cotton is placed over the upper lip below the nostril. If cotton flutters down it indicate nasal breathing.

Management:-

1)Elimination of the cause- If nasal or pharyngeal obstruction has been diagnosed then removal of the cause is done by surgery .

2) Interception of the habit-

a)Physical Exercise

b)Lip Exercise

3) Oral Screen –¬ The most effective way to reestablish nasal breathing is to prevent air entering the oral cavity .

holes should be found in it and begain to close it gradually.

<u>Bruxism</u>

Bruxism is a grinding of teeth and is usually reported to occur while a child is sleeping.

Masticatory muscle soreness and temporomandibular joint pain have also been attributed to bruxism.

The exact cause of significant bruxism is unknown, although most explanations center around local, systemic, and psychological reasons.

The local theory suggests that bruxism is a reaction to an occlusal interference, high restoration, or some irritating dental condition.

Systemic factors implicated in bruxism include intestinal parasites, subclinical nutritional deficiencies, allergies, and endocrine disorders.

The psychological theory submits that bruxism is the manifestation of a personality disorder or increased stress.

Treatment should begin with simple measures. Occlusal interferences should be identified and equilibrated if necessary.

If occlusal interferences are not located or equilibration is not successful, referral to appropriate medical personnel should be considered to rule out any systemic problems.

If neither of these two steps is successful a mouthguard like appliance can be constructed of soft plastic to protect the teeth and attempt to eliminate the grinding habit.

If the bruxism appears to be a stress response, stress management, behavioral therapy, or biofeedback may be effective.

Nail biting

It is most common habit in children

- It is sign of internal tension

Etiology :-

- Persistence nail biting may be indicative of emotional problem
- Psychosomatic
- Successor of thumb sucking

Clinical features:-

- Crowding
- Rotation
- Alteration of incisal edge of incisor
- Inflammation of nail bed.

Management:-

- Patient is made aware of problem.
- Treat the basic emotional factor causing the act.
- Encouraging outdoor activity which may help in easing tension.
- Application of nail polish, light cotton mittens as reminder

Conclusion

The identification and assessment of an abnormal habits and its immediate and long-term effect on the craniofacial complex and dentition should be made as early as possible to minimize the potential deleterious effect on dentofacial Complex.

References

-Proffit, WR, Fields, HW. 2012. Contemporary orthodontics. 5th ed. St. Louis (MO): Mosby Elsevier.
-Simon j.Littlewood and Laura Mitchell 2019 An introduction to Orthodontics Fifth Edition
-Graber TM (2000) Orthodontics Principles and practice, Missouri: Mossby C.
-T. D. FOSTER (1990) A Textbook of Orthodontics Third edition
-Textbook of Pediatric 3rd Edition Prof S.G dentistry Damle

Orthodontic treatment plan phases

Ass. Prof. Zena Hekmat

Orthodontic treatment plan phases are

1-Preventive Orthodontics

2- Interceptive Orthodontics

3-Corrective Orthodontics

Preventive Orthodontics: Includes all those procedures undertaken to preserve the integrity of normally developing occlusion by protecting current conditions or preventing situations that would interfere with growth by the following measures

-Parent education

-Maintenance of shedding and eruption timetable

-Management of premature loss of deciduous teeth (Space maintainers)

- Management of ankylosis of deciduous teeth

- Prolonged retention of deciduous teeth

-Extraction of Supernumerary Teeth

- Management of Oral Habits

-Treatment of Occlusal Prematurity

-Management of Abnormal Frenum Attachment

- **Interceptive orthodontics:** "that phase of science and art of orthodontics employed to recognize and eliminate potential irregularities and malpositions in the developing dentofacial complex"

Interceptive Orthodontics:

Interceptive orthodontics is undertaken at a time when malocclusion has already developed or developing. The difference between preventive and interceptive orthodontics lies in the timing of the services rendered. Preventive orthodontic procedures are undertaken when the dentition and occlusion are perfectly normal, while the interceptive procedures are carried out when signs and symptoms of a developing malocclusion are evident.

Interceptive orthodontic procedures may include:

1-serial extraction

2-Correction of developing cross-bites

3-Control of abnormal oral habits

4-Proximal stripping of deciduous teeth to facilitate the eruption of adjacent permanent teeth

5-Correction of occlusal interferences

6-Interception of skeletal malrelations

7- Space regaining

9-Muscle exercises

Corrective early treatment:

Complete or nearly complete correction of an orthodontic problem.

e.g. Expansion appliances, growth modification appliances, alignment of anterior teeth.

Overall goal of early treatment:

To improve or correct orthodontic problems that would result in:

- Irreversible damage to the dentition and supporting structures.
- Progression into a more severe orthodontic problem that would be more difficult to treatment in Phase II.

Serial Extraction

- Serial Extraction: A planned sequence of tooth removal during the transition from primary to permanent dentition to promote eruption of teeth through attached gingiva (keratinized tissue) and reduce the severity of crowding.
- Eruption sequence of the permanent dentition
- : Maxilla: 6 1 2 4 5 3 7 8
- Mandible: 6 1 2 (3 4) 5 7 8

Case selection:

1. No skeletal disproportions
2. Class I molar relationship
3. Non-retrusive lip profile
4. Normal overbite

5. Coincident midlines

6. Not in case of severe crowding.

procedure:

Extraction of Cs as soon as the permanent incisors complete their eruption, such extraction will allow spontaneous relief of crowding.

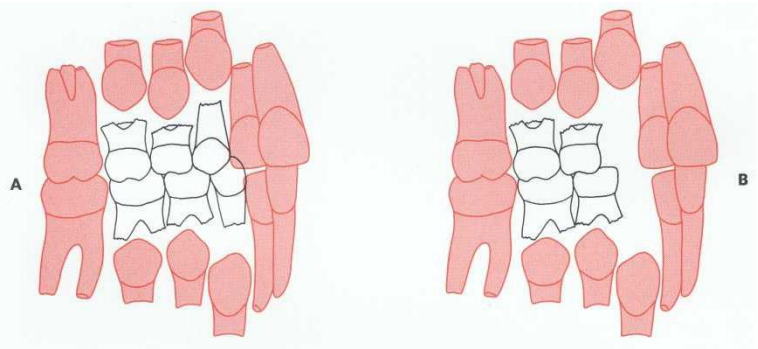

Extraction of Ds, and this is done after an accepted alignment of the incisors.

The aim of these extractions is to accelerate the eruption of the permanent first premolar.

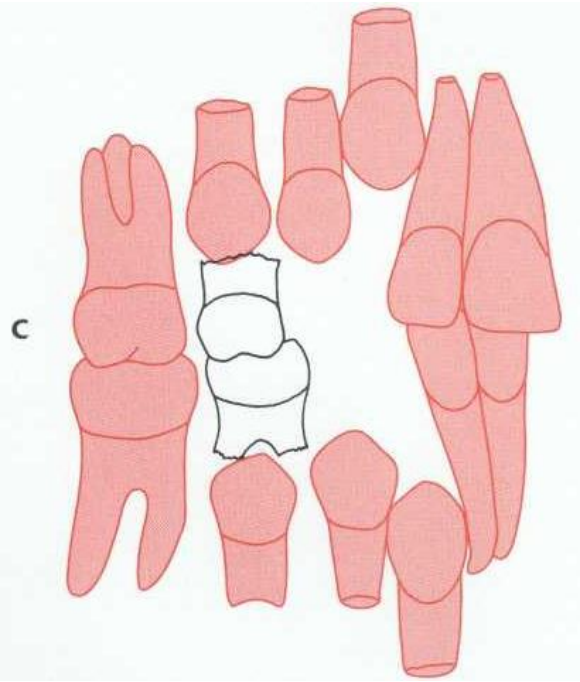

Extraction of permanent first premolar as soon as they emerge from the oral mucosa, thus allowing the space for the canines and 2nd premolars to occupy the space mesial to 6s and distal to 2s.

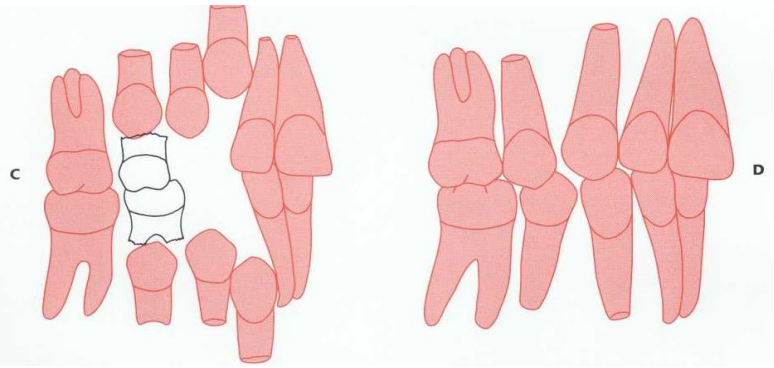

I. CASES NEED ENUCLEATION IN THE MANDIBLE :

- Treatment Procedure :

I. *Extraction of the primary first molars and enucleation of the mandibular first premolars :*

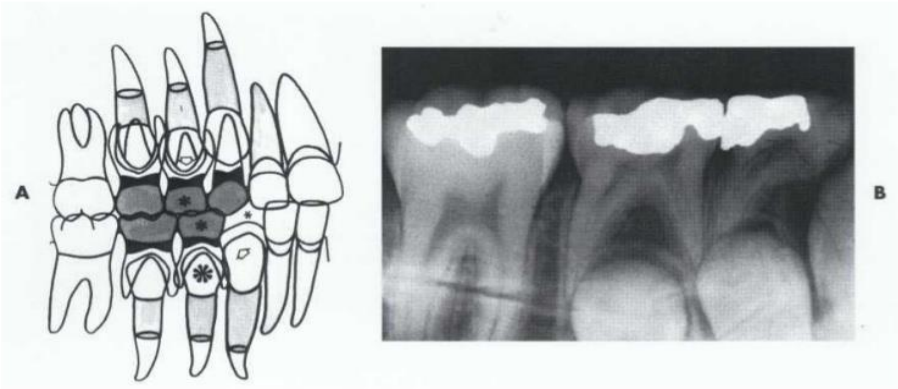

2. *Extraction of the primary maxillary canines and maxillary first premolars:*

In the maxilla the first premolars usually emerge before the canines. Therefore enucleation is less likely to be indicated.

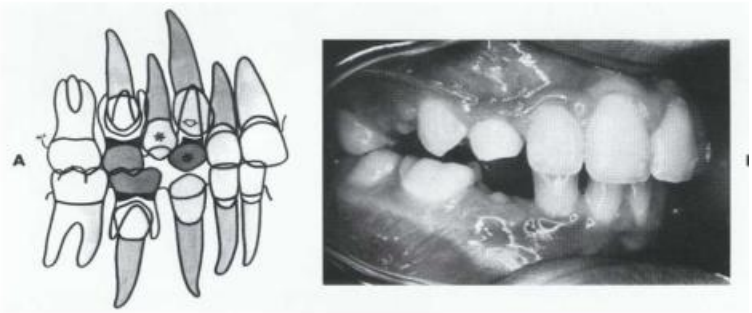

Complication

-A complication can occur if the primary first molar is extracted early and the first premolar still does not erupt before the canine. This can lead to impaction of the premolar that requires later surgical removal .

-Loss of some arch perimeter.

-Concave profile.

- Increase in overbite.

-Not enough to solve the problem (alone).

A complete diagnostic aids should be taken before starting the S.E. procedure and the patient should have at least beside clinical examination an OPG that can demonstrate the existence of the complete dentition at the beginning of the treatment.

All the local factors that worsen the crowding should be avoided during the treatment such as presence of supernumerary tooth, as early loss of primary Es or bad conservative work for the rest of the remaining teeth.

Advantage

immediate relief of crowding or malocclusion.

Less time consuming and low cost especially if at the end, the teeth arranged with good alignment.

-Simple procedure

-Less duration of wearing orthodontic appliances

DISADVANTAGES:

- Requires clinical judgment
- Prolonged treatment time(2-3 years)
- Patient compliance(multiple visits)
- Psychological trauma of extraction.

- Possibility of developing tongue thrust
- Arch length reduction
- Ditching between canine and second premolar
- Axial inclination should be corrected later.

In a lot of cases the final outcome of teeth alignment is accepted by the parent, patient and even the dentist. However, an upper and lower fixed appliance are needed to give the final touches….

The appliances are worn for 6-8 months only rather than 2-2.5 years.

References

-Proffit, WR, Fields, HW. 2012. Contemporary orthodontics. 5th ed. St. Louis (MO): Mosby Elsevier.

-Simon j.Littlewood and Laura Mitchell 2019 An introduction to Orthodontics Fifth Edition

-Graber TM (2000) Orthodontics Principles and practice, Missouri: Mossby C.

-T. D. FOSTER (1990) A Textbook of Orthodontics Third edition

Ortho.Lec.10 2019/2020 5th class Lecturer Zainab Bahgat

Orthodontics and orthognathic surgery

Orthognathic surgery is concerned with the correction of dento-facial deformity. In the vast majority of cases a combined surgical and orthodontic approach is required to achieve an optimum result.

Indications for Orthognathic Surgery

- ✓ Severity of skeletal and dental malocclusion
- ✓ When growth modification can not be achieved
- ✓ Esthetic and psychosocial considerations
- ✓ Good general health status (mild, controlled systemic disease)
- ➢ For patients whose orthodontic problems are so severe that neither growth modification nor camouflage offers a solution, surgery to realign the jaws or reposition dentoalveolar segments is the only possible treatment.

Surgery is not a substitute for orthodontics in these patients. Instead, it must be properly coordinated with orthodontics and other dental treatment to achieve good overall results

The patient's perception of the problem

- ➢ appearance
- ➢ masticatory difficulties
- ➢ speech
- ➢ traumatic overbite
- ➢ temporomandibular joint dysfunction

CAMOUFLAGE VERSUS SURGERY

- The decision for camouflage or surgery must be made before treatment begins, because the orthodontic treatment to prepare for surgery often is just the opposite of orthodontic treatment for camouflage

- It is a serious error to attempt camouflage on the theory that if it fails, the patient can then be referred for surgical correction. At that point, another phase of "reverse orthodontics" to eliminate the effects of the original treatment will be required before surgery can provide both normal jaw relationships and normal occlusion.

Extraction of Teeth and the Camouflage/Surgery Decision

- The critical importance of deciding on camouflage or surgery at the beginning of treatment is illustrated by the difference in extractions needed with the two approaches
- In camouflage, extraction spaces are used to produce dental compensations for the jaw discrepancy and the extractions are planned accordingly.
- Some degree of dental compensation accompanies most skeletal jaw discrepancies, even without treatment.
- If the jaws are to be repositioned surgically, this dental compensation must be removed. Otherwise, when the teeth are placed in normal occlusion, the jaw discrepancy will not be totally corrected, and dental interferences make it almost impossible to put the jaws in their proper relationship to each other

Computer Simulation of Alternative Treatment Outcomes

- It always has been a moral and ethical imperative to allow the patient to make important decisions about what treatment he or she will accept
- Computer image predictions are particularly valuable in helping patients decide between camouflage and surgery, and in planning surgical treatment.
- The patient can view the impact on the soft tissue profile of orthodontic camouflage versus surgery when these are realistic treatment alternatives
- also view the effect of varying amounts of surgical change—more or less mandibular advancement, for example, or the effect of genioplasty or rhinoplasty in addition to change in jaw position.

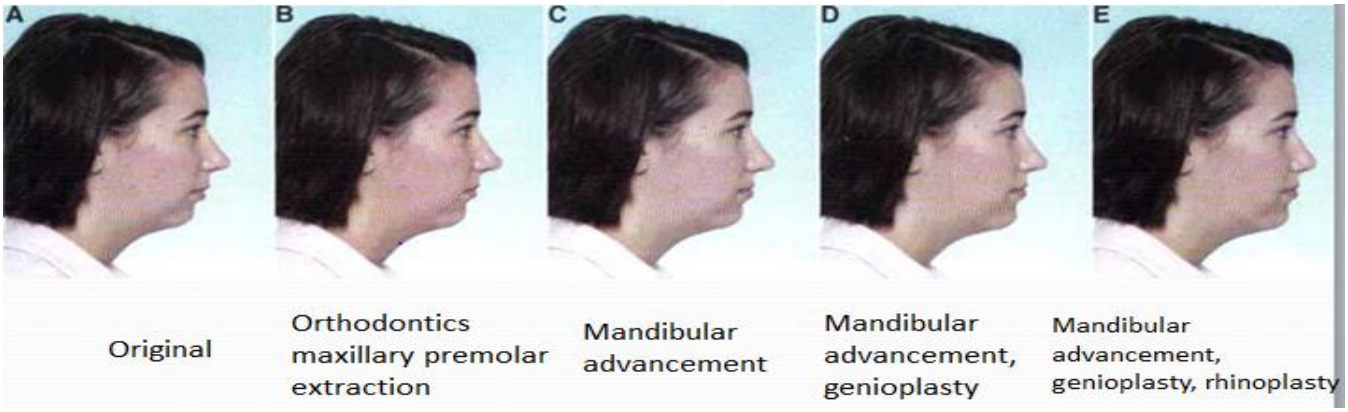

The characteristics of a patient who would be a good candidate for camouflage treatment are:

- **Too old for successful growth modification**
- **Mild to moderate skeletal Class II or mild skeletal Class III**
- **Reasonably good alignment of teeth (so that the extraction spaces would be available for controlled anteroposterior displacement and not used to relieve crowding)**
- **Good vertical facial proportions, neither extreme short face (skeletal deep bite) nor long face (skeletal open bite)**

Camouflage treatment designed to correct the occlusion despite jaw relationship problems <u>should be avoided in :</u>

- ***Severe Class II , moderate or severe Class III , and vertical skeletal discrepancies.***
- ***Patients with severe crowding or protrusion of incisors ،in whom space created by extractions will be required to achieve proper alignment of the incisors.***
- ***Adolescents with good growth potential (in whom growth modification should tried first) or non-growing adults with more than mild discrepancies (in whom orthogenetic surgery usually offers better long-term results).***

COMMON SURGICAL PROCEDURES

As aesthetics are of major importance, where possible an intra-oral approach should be used to avoid unsightly scars. Segmental procedures have an increased morbidity, as damage to the teeth or disruption of the blood supply to a segment is more likely.

Maxillary procedures

- **Segmental procedures The Wassmund technique involves movement of the upper premaxillary segment of incisors and canines as a block,**
- **Le Fort I This is the most widely used technique. The standard approach is a horseshoe incision of the buccal mucosa and underlying bone, which results in the maxilla being pedicled on the palatal soft tissues and blood supply.**
- **Le Fort II to achieve mid-face advancement**
- **Le Fort III the whole mid-face including the zygomas is separated from the cranium**

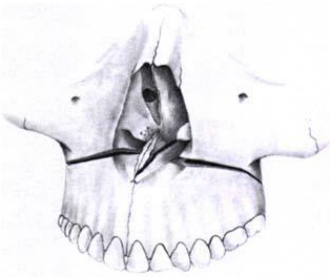

Le Fort I **Le Fort II** **Le Fort III**

Mandibular procedures

- **Vertical subsigmoid osteotomy**
- **Sagittal split osteotomy**
- **Sub-apical osteotomy**
- **Body osteotomy**
- **Genioplasty**

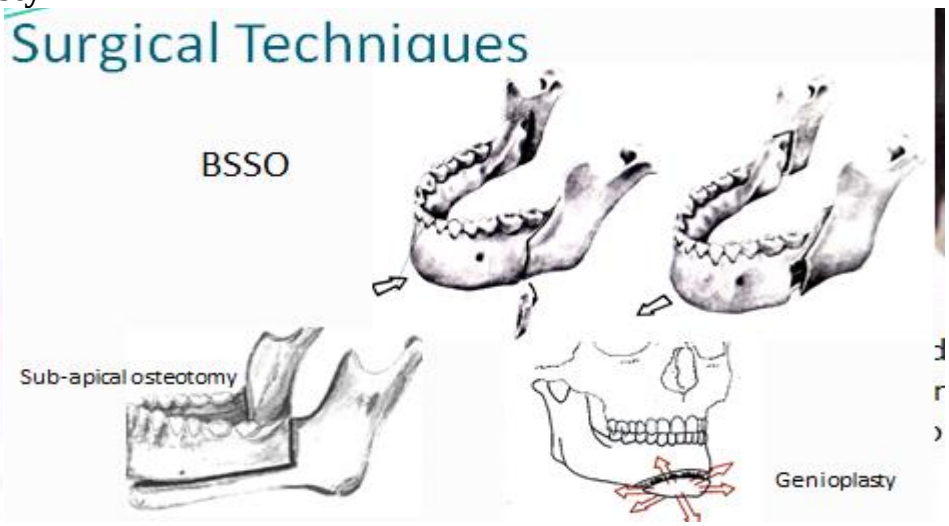

Documentation

Standard records should include:

- **a detailed description of the patients' concerns**
- **facial and dental photographs**
- **dental study casts usually based in centric occlusion**
- **an orthopantomogram (OPT) and lateral cephalogram, with a postero-anterior (PA) cephalogram for those patients presenting with an asymmetry**
- **a detailed dental history and examination**
- **a detailed medical history and examination**

Timing of Surgery

- **Usually done when all growth is complete**
- **Assessed by superimposition of serial lat cephs**
- **Can be performed when growth is not yet complete in cases of psychosocial problems or great severity when function is compromised (i.e. breathing, chewing**

Correction of A-P relationships:

- **maxillary advancement**
- **retraction of anterior maxillary segment**
- **mandibular advancement**
- **mandibular setback**
- **double jaw surgery**

- **The maxilla and mandible can be moved anteriorly and posteriorly**
- **Anterior movements of the mandible greater than 10 to 12 mm create considerable tension in the investing soft tissues and tend to be unstable. Anterior movement of the maxilla is similarly limited to 7-8 mm in most circumstances.**
- **Posterior movement of the entire maxilla, though possible, is difficult and usually unnecessary. Instead, posterior movement of protruding incisors up to the width of a premolar is accomplished by removal of a premolar tooth on each side, followed by segmentation of the maxilla.**
- **Although the maxilla can be advanced more than it can be retracted, the possibility of relapse or speech alteration from nasopharyngeal incompetence increases with larger movements.**

Correction of Vertical Relationships

- ✓ **maxillary impaction/intrusion**
- ✓ **maxillary extrusion**
- ✓ **mandibular ramus surgery**

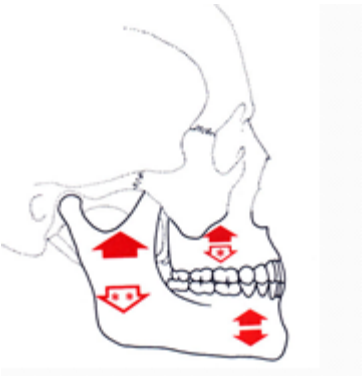

The surgical movements in the vertical dimension are indicated by the red arrows on this diagram of the skull. The maxilla, mandibular angles, and chin can be moved upward reliably, while downward movement of the maxilla by bone grafting is less predictable *(arrow with single asterisk).* Downward movement of the chin is possible in combination with slight advancement. Lengthening the ramus *(arrow with double asterisks)* stretches the muscular sling and usually results in relapse

Distraction Osteogenesis

- **Distraction osteogenesis is based on manipulation of a healing bone, stretching an osteotomized area before calcification has occurred in order to generate the formation of additional bone formation and investing soft tissue**
- **Distraction osteogenesis is useful for the correction of severe deformity in the growing child and it is hoped will help to reduce the number of surgical procedures previously required to treat these children.**

The advantages of distraction are that

(1) larger distances of movement are possible than with conventional orthognathic surgery, and the forces also act upon the surrounding soft tissues leading to adaptive changes termed distraction histogenesis

(2) deficient jaws can be increased in size at an earlier age.

- **<u>The great disadvantage is that precise movements are not possible</u>. With distraction, the mandible or maxilla can be moved forward, but there is no way to position the jaw or teeth in exactly a pre-planned place,**

Orthodontic Appliance Considerations

- **In contemporary surgical-orthodontic treatment, a fixed orthodontic appliance has three uses: to**

(1) accomplish the tooth movement needed in preparation for surgery;

(2) stabilize the teeth and basal bone at the time of surgery and during healing; and

(3) allow the necessary postsurgical tooth movement while retaining the surgical change

Pre Surgical Orthodontic Objectives

- ✓ **To level and align the arches and make them compatible so that the teeth do not interfere with placing the jaws in their planned relationship**
- ✓ **to resolve crowding and/or spacing**
- ✓ **to establish anteroposterior and vertical position of incisors (decompensate) to place teeth relative to their own supporting bone**
- ✓ **It is important to forewarn the patient that the presurgical orthodontic phase may make their appearance worse as any dento-alveolar compensation is reduced**
- ✓ **Presurgical orthodontics usually takes between 12 and 18 months depending upon the complexity of the case**

Preparation for Surgery

- ➢ **Removal of third molars 6 months before mandibular osteotomy**
- ➢ **Check for any TMJ problems**
- ➢ **Manipulate models mounted in an articulator to check for interferences and occlusion**
- ➢ **Model surgery is often carried out to determine the amount and site of bone removal and to fabricate inter-occlusal wafers Splint fabrication (1 or 2 splints usually 1 to 2 weeks before surgery**

Post Surgical Orthodontic Treatment

- ▪ **4-6 weeks: reinitiate orthodontic tx (after range of motion and stability are achieved) remove splint**
- ▪ **change to light wires and light vertical elastics**
- ▪ **treatment usually completed in 4 to 12 months (average 6 months)**

Relapse and Stability

- **Rigid fixation has improved stability**
- **Stability is mostly influenced by the pattern of rotation of the mandible as it is advanced**
- **Advancement of maxilla and/or mandible will stretch soft tissues promoting relapse**
- **The more advancement needed, the greater the probability for relapse**
- **patient is compliant with all aspects of treatment, particularly postsurgical wear of elastic traction**

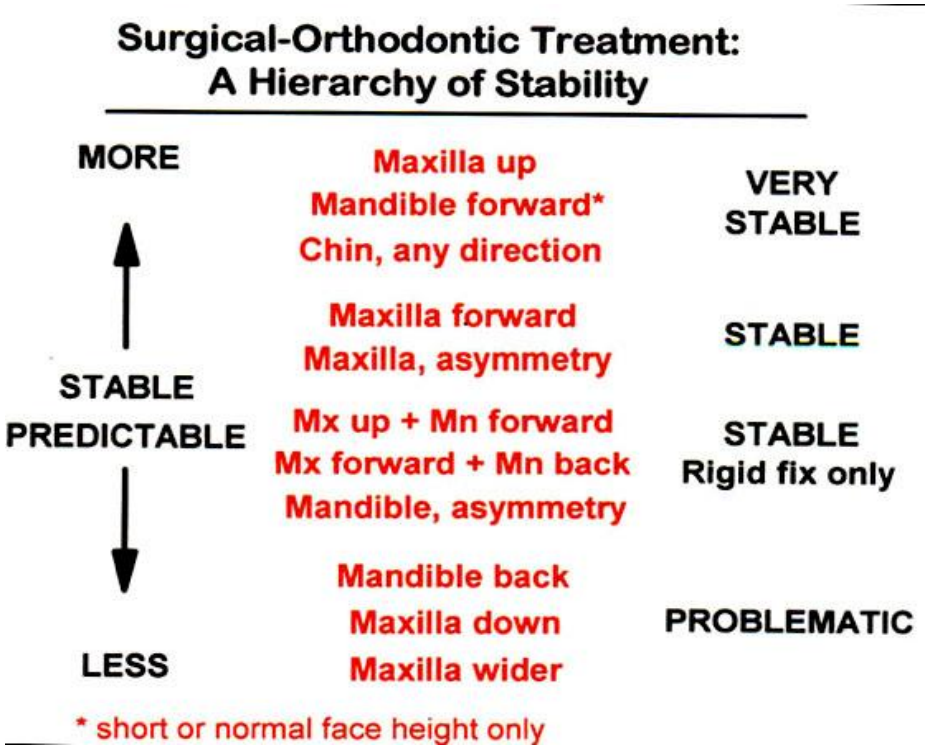

- **In this context, very stable means better than a 90% chance of no significant postsurgical change; stable means better than an 80% chance of no change and major relapse quite unlikely; problematic means some degree of relapse likely and major relapse possible.**

- **It is interesting to note that the key procedures in surgical treatment of Class II problems (superior repositioning of the maxilla , mandibular advancement and their combination) are quite stable. In Class III treatment, maxillary advancement is the most stable procedure, while downward movement of the maxilla and mandibular setback remain problematic).**

Refrences

-An Introduction to Orthodontic.fourth edition 2013 United Kingdom--Laura Mitchell, MBE Oxford

-CONTEMPORARY ORTHODONTICS , FifTH EDITION 2013--WILLIAM R. PROFFIT, MOSBY

--Textbook of Orthodontics Second Edition: 2007--Gurkeerat Singh, Jaypee New Delhi 110 002, India

--ORTHODONTIC REVIEW, SECOND EDITION 2015--Jeryl D. Sercan Akyalcin -Timo Peltomäki -Kate Litschel, by Mosby, an imprint of Elsevier Inc

Ortho.Lec.8 2019/2020 5th class Lecturer Zainab Bahgat

CLASS III MALOCCLUSION

Class III malocclusion A malocclusion that is:very easy to identify but is often difficult to treat

Orthodontic treatment not only involves establishment of physiologically and anatomically functional occlusion but also includes correction of the relationship of the maxilla and mandible to each other and to the rest of the craniofacial complex

Skeletal Class III malocclusion can be defined as skeletofacial deformity characterized by a forward mandibular position with respect to the cranial base and maxilla. The facial dysphasia can be classified into mandibular prognathism, maxillary retrognathism or combination of both depending variation of the anteroposterior jaw relation

According to British standards Incisor classification, in class III malocclusion the lower incisor edges lie anterior to the cingulum plateau of the upper incisors. The overjet is reduced or reversed.

According to Angle's classification, in class III the mesiobuccal cusp of the lower first molar occludes mesial to the class I position ***(mesioocclusion)***

- Vertically they can be classified as, long ,average and short face. To obtain an accurate diagnosis of class III malocclusions, a through evaluation of the clinical data is necessary include:

  - 1) Age, Sex, and family history of patients.
  - 2) Molar relationship; careful assessment.
  - 3) Craniofacial morphologic characteristics: i.e. maxilla and mandible relation to cranial base, intermaxillary relationship, mandibular plane angle, gonial angle and vertical dimension.
  - 4) Position of maxillary and mandibular incisor.
  - 5) Soft tissue appearance : frontal and profile views can identify the skeletal class III problem.
  - 6) Functional Shift :- Some ant crossbite and skeletal class III patients shows functional shift, due to premature contact between maxillary and mandibular incisors

CLASSIFICATION Class III

DENTAL **SKELETAL**

TRUE **PSEUDO** **TRUE**

Occlusal features

- A Class III molar relationship.
- A Class III canine relationship.
- A reverse overjet with possibly labially inclined upper incisors and lingually lower incisors .
- A posterior cross-bite unilateral or bilateral (or functional) due to a constricted maxillary arch or a more forward positioned lower arch

CEPHALOMETRIC CLASSIFICATION

- **Dentoalveolar Class III**:
- No apparent sagittal skeletal discrepancy (normal ANB angle)
- Tipping of incisors : upper- lingual and lower -labial
- **Skeletal Class III:**
- Cranial base :- the linear and angular measurements of the cranial base were decreased. Cranial base angle is acute and exhibited a more anteriorly positioned articulare compared with Class I malocclusion. Middle cranial fossa is in Class III patients has posterior and superior alignmet. This alignment positions the nasomaxillary complex in more retrusive relation and contributes to a forward rotation of the mandible.
- Max retrusion , Mand prognathism or Combination
- Negative to 0 ANB angle
- Increased mand length and more obtuse gonial angle
- Tipping of incisors: upper- labial & lower lingual (compensation)
- **Pseudo Class III** Ceph values intermediate to class I & III. The only exception was the gonial angle, which was more obtuse in skeletal Class III sample. measurement of gonial angle in pseudo Class III was found to be similar to Class I sample. ***This is main key point in pseudo and Class III***

ETIOLOGY

- True Class III malocclusion exhibits(Underlying skeletal imbalance) usually inherited have a very strong GENETIC basis.
- Habitual forward positioning of the mandible (Pseudo Class III) for example Occlusal prematurities, Enlarged adenoids
- In additions Rakosi and Sehilli suggested a role for environmental influences such as habits and mouth breathing in the etiology of Class III malocclusion. They hypothesized that excessive mandibular growth could arise as a result of abnormal mandibular posture because constant distraction of the mandibular condyle from the fossa may be a growth stimulus

Causes of an reversed overjet

cause	Aetiology
Skeletal pattern (Class III)	- Long mandible - Forward placement of glenoid fossa positioning the mandible more anteriorly - Short and/or retrognathic maxilla - Short anterior cranial base
Anterior mandibular displacement on closure	- Premature contact
Retained primary upper incisors	These may deflect the eruption path of their successors palatally into crossbite
Restrained of maxillary growth	- Found in repaired cleft lip & palate & attributed to the effect of postsurgical scar tissue

features of true and pseudo class III

True class III	**Pseudo class III**
• Concave profile	**Straight / concave**
• a class **III** skeletal pattern,	**a class I skeletal pattern,**
• No premature contacts	**Premature contacts present**
• Forward path of closure	**Deviated path of closure**
• Gonial angle increased or decreased.	**Normal gonial angle**
• Retrusion of mandible is not possible	Retrusion of mandible is possible

Treatment planning in class III malocclusions

♦ Many factors should be considered before planning the treatment:

1. **The patients opinion** regarding their occlusion and facial appearance.
2. **The severity of the skeletal pattern**. both- Anteroposteriorly &- Vertically(The major determinant of the difficulty & prognosis of orthodontic treatment).
3. **The expected pattern of future growth**. Both anteroposteriorly &vertically Children with increased vertical proportions The average growth tend to often continue to exhibit Worsening a vertical pattern of the relation between the arches. which reduce the overbite.
4. **Overbite** in Class III malocclusions normal or increased overbite is an advantage as a vertical overlap of the upper incisors with the lower incisors post-treatment is vital for stability.
5. **If the patient can achieve an edge-to-edge incisor position**: Increase the prognosis of correction the incisor relationship.
6. **Dento-alveolar compensation**. Orthodontic treatment aimed to increase it, if it already present, trying to increase it further may not be an aesthetic or stable treatment option.
7. **The degree of crowding**. • crowding occurs more frequently, and to a greater degree, in the upper arch. Extractions should be resisted as it worsening the incisor relationship. Where upper extractions are necessary, it is advisable to extract at least as forwards in the lower arch.

♦ Class III malocclusion characterized by upper arch length deficiency and anterior cross bite

To relief upper arch crowding Additional space can be gained by**:**

1. **Expansion the arch Anteriorlly** to correct anterior cross-bite to correct the incisor relationship and/or
2. **Expansion the arch Buccoligually** to correct buccal segment cross-bite, will have the effect of reducing overbite, which is a disadvantage in Class III (overbite reduction occurs because expansion of the upper arch is achieved primarily by tilting the upper premolars & molars buccaly) palatal cusps swinging and 'propping open' the occlusion.

   If upper arch expansion is indicated & the overbite is reduced Fixed Appliances should be used to limit tilting of upper molars buccally during expansion.
3. **Distal movement of the upper buccal segment** with Headgear to gain space for alignment (is inadvisable in growing patient due to restraining growth of maxilla).

Mild to Moderate Crowding, space can be made by a Combination of 1. forward movement of the incisors & 2. distal movement of the remaining buccal segment teeth

♦ In case of sever arch length deficiency involving both the arches, the first premolars should be extracted in both the upper and lower arches

Treatment modalities

1. Growth modification 2. Orthodontic correction 3. Surgery

Class III malocclusion should be recognized and treated early due to the

- The **reasons for early treatment:**

1. To correct the anterior displacement of the mandible before the eruption of the canine and premolars so that they can be guided into a Class 1 Relationship

2. To provide space for the eruption of the BUCCAL segments as a result of Proclination of the upper incisor

3. to provide a normal environment for the growth of the maxilla by Elimination the Anterior Crossbite

4. Psychological benefits resulting from improved dental and facial appearance.

Interception during growth

Orthopedic appliance What is Orthopedic appliance ? ♦ Orthopedic appliance that allows orthodontists to control growth of facial structures it is:

♦ Various designs

♦ Used with growing patients

Class III malocclusions that are a result of maxillary retrusion can be treated by **reverse headgear or face mask** to protract the maxilla

Maxillary skeletal appliances face mask (Reverse Pull Headgear)

APPLIANCE DESIGN: ♦ The orthopedic facial mask consists of three basic components.

- ❖ FACIAL MASK
- ❖ BONDED /BANDED MAXILLARY SPLINT
- ❖ ELASTICS

♦ The facial mask : an extra oral device composed of **a fore head pad** ,**a chin pad** that are connected with **a heavy steel support rod**. To this support rod is connected **a cross bow to which are attached rubber bands** to produce a forward and downward elastic traction of the maxilla. The position of the pads and the cross bow can be adjusted simply

♦ (Require a Very Cooperative Patient)♦ Used to apply an anteriorly directed force, via ELASTICS, on the maxillary teeth and maxilla

The face mask is most effective in the treatment of mild to moderate skeletal Class III malocclusions with a retrusive maxilla

♦ This technique also useful in Class III associated with a CLP anomaly & hypodontia where forward movement of the buccal segment teeth to close space is desirable.

♦ Side effects include/downward and backward rotation of the mandible/Lingual tipping of the mandibular incisors

Treatment timing for Orthopedic facial Mask Therapy: Recent studies showed first treatment of Class III malocclusion with facial mask in early mixed dentition results in more favorable for craniofacial changes than in late mixed dentition. This is mainly due to changes in maxillary suture which leads to forward displacement of maxilla in early mixed dentition. All these observation suggest that the early mixed dentition phase of dental

development is most appropriate period to perform treatment of Class III malocclusion with the orthopedic facial mask.

In a prospective clinical trial, overjet correction was found to be the result of forward maxillary movement (3 1 %), backward movement of the mandible (2 1 %), labial movement of the maxillary incisors (28%), and lingual movement of the mandibular incisors (20%).

B

SKELETAL EFFECTS OF MAXILLARY PROTRACTION (sutures involved): The maxilla articulates with nine other bones of the craniofacial complex: frontal, nasal, lacrimal, ethmoid, palatine, vomer, zygoma, inferior nasal concha, opposite maxilla, and occasionally sphenoid. Palatal expansion had been shown to produce a forward and downward movement of the maxilla by affecting the intermaxillary and circummaxillary sutures. The disruption of these sutures may help initiating cellular response in the sutures, allowing a more positive reaction to protraction.

- ***Chin cup therapy*** Skeletal Class III malocclusion with relatively normal maxilla and moderately protrusive mandible can be treated with the use of a chin cup.
- Early treatment with chin cup provides better growth inhibition or redirection and post positioning of the mandible.
- Effects on mandibular growth: The orthopedic effects of a chin cap on mandible includes

  1. Redirection of mandibular growth vertically.
  2. Backward rotation of mandible.
  3. Remodeling of mandible with closure of the gonial angle

- **Effects on Maxillary growth**: Some studied have indicated that a chincap appliance has no effect on antero posterior growth of the maxilla. But early correction of an anterior crossbite with chincap prevents retardation of A-P maxillary growth.
- :Chin caps are divided into two types
- 1) occipital chin cap that is used for patients with mandibular protrusion.
- 2) Vertical pad chin cap used in patient with steep mandibular plane angle and excessive anterior facial height.

Force magnitude and duration

- **Orthopedic force is about 300-500 gm / side**. Patient is in instructed to wear 14 hr/day. The orthopedic force is usually dilevered either through the condyle or below the condyle
- ***Treatment timing and duration***: Patient with mandibular excess usually recognized in the primary dentition because most of children will have retrusive mandible. To reduce the mandibular protrusion is more successful when treatment is started in primary or early mixed dentition. The treatment time varies from 1 year to as long as 4 year depending on the severity of the original malocclusion. The stability of chin cup treatment remains unclear. Several investigators reported a tendency to return to the original growth pattern after the chin cup is discontinued.

<u>Functional appliances</u>⁄**Frankel III**, a mayofunctional appliance can be used during growth to intercept Class III malocclusion due to maxillary skeletal retrusion.

- The Frankel III (FRIII) regulator is a functional appliance designed to counteract the muscle forces acting on the maxillary complex.
- According to Frankel the vestibular shields in the depths of the sulcus are placed away from the alveolar buccal plates of the maxilla to stretch the periosteum and allow for forward development of the maxilla.
- The shields are fitted closely to the alveolar process of the mandible to hold or redirect growth posteriorly. The effectiveness of each appliance is dependent on patient cooperation and wearing them full time.

can be useful in mixed dentition where a combination of¬ Proclination of the upper incisors together with¬ Retroclination of the lower incisors is required.

<u>Orthodontic correction</u>

Can be achieved by either(i)- Proclination of the upper incisors alone **or(ii)-** Retroclination of the lower incisors with or without proclination of the upper incisors.

This determined by: – Skeletal pattern & – Amount of overbite present before treatment

Proclination of the upper incisors **decrease** the Overbite. Retroclination of the lower incisors **increase** the Overbite

<u>Treatment options:</u>

1. Accepting the incisor relationship:(a) - in mild cases where the overbite is minimal;(b) - if the remainder of the family have a similar facial appearance.

2. Proclination of the upper labial segment: Best carried out in the mixed dentition when the canines are unerupted and high above the roots of the upper lateral incisors.

Correction of the incisors relationship by proclination of the upper incisors only can be considered in cases with the following features:

a) A Class I or mild Class III skeletal pattern.

b) The upper incisors are not already proclined.

c) An adequate overbite will be present at the end of treatment to retain the corrected position of the upper incisors.

3. Retroclination of the lower labial segment with or without proclination of the upper labial segment*:*⁄In those cases with a mild to moderate Class III skeletal pattern, or where there is reduce overbite, A combination of retroclination of the lower incisors and proclination of the upper incisors will achieve correction of incisors relationship.

To advance the upper incisors & retrocline the lower incisors can be done by:

- Removable appliances,
- Functional appliances&
- Fixed appliances: tooth movements are accomplished more efficiently

. For retroclination the lower labial segment Space is required in the lower arch &Extractions are required unless the arch is spaced naturally.

Role of extractions

♦Extraction of the lower deciduous canines may allow the lower incisors to drop lingually and assist in the correction of the reverse overjet.

.

Retroclination of the lower labial segment with or without proclination of the upper labial segment:♦ Use of a ROUND archwire in the lower arch & a RECTANGULAR arch in the upper arch help to correct the incisors relationship.♦ Intermaxillary Class III elastic traction from the lower labial segment to the upper molars can also be used to help move the upper arch forwards & the lower arch backwards(care required to avoid extrusion of the molars which will reduce overbite.

Surgery

♦ Sever skeletal pattern and/or♦ reduced overbite or♦ an anterior openbite(Precludes orthodontic alone)

Surgery is almost requiredif the value for ANB ^{0} < – 4° & The inclination of the lower incisors to the mandiblar plane < 83°.

Treatment of severe Class III after growth

- Class III Maxillary deficiency Lefort I osteotomy
- Class III Mandibular prognathism Mandibular set back:
  - Sagittal split osteotomy procedures
  - Body ostectomy or
- Prominent chin : reduction Genioplasty

POST SUGICAL ORTHODONTICS Can be initiated 3 to 4 weeks after the release of immobilization. Stabilization arch wires are removed and replaced by working arch wires with light vertical forces till a good stable occlusion is achieved.

Refrences

-An Introduction to Orthodontic.fourth edition 2013 United Kingdom--Laura Mitchell, MBE Oxford

-CONTEMPORARY ORTHODONTICS , FifTH EDITION 2013--WILLIAM R. PROFFIT, MOSBY

--Textbook of Orthodontics Second Edition: 2007--Gurkeerat Singh, Jaypee New Delhi 110 002, India

--ORTHODONTIC REVIEW, SECOND EDITION 2015--Jeryl D. Sercan Akyalcin -Timo Peltomäki -Kate Litschel, by Mosby, an imprint of Elsevier Inc

Class II Malocclusion

Angle's class II the mesiobuccal cusp of the lower first molar occludes distal to the Class I position. This is also known as a postnormal relationship.

class II subdivision a class II molar relation in one side and class I molar in the other side .

Angle's classification was based upon the premise that the first permanent molars erupted into a constant position within the facial skeleton, which could be used to assess the anteroposterior relationship of the arches. In addition to the fact that Angle's classification was based upon an incorrect assumption, the problems experienced in categorizing cases with forward drift or loss of the first permanent molars have resulted in this particular approach being superseded by other classifications. However, Angle's classification is still used to describe molar relationship, and the terms used to describe incisor relationship have been adapted into incisor classification.

- **According to British Standards classification:**

CLASS II DIVISION 1 "The lower incisor edges lie posterior to the cingulum plateau of the upper incisors, there is an increase in overjet and the upper central incisors are usually proclined."

CLASS II DIVISION 2 The lower incisor edges lie posterior to the cingulum plateau of the upper incisors. The upper central incisors are retroclined, because of high lower lip line. Overjet is usually minimal or may be increased."

- ***Von-Der-Linden classified Angle's class II/2 malocclusion in to 3 types based on the severity of incisor relationship :***

Type A: Maxillary central incisors and laterals are retroclined. Degree of retroclination is less severe in nature.

Type B: Maxillary lateral incisors are overlapping the retroclined maxillary central incisors.

Type C : Maxillary central and lateral incisors Are retroclined and are overlapped By the maxillary canines.

Features of Class II Division 1

- Proclined maxillary anteriors with resultant inc overjet.
- Proclined maxillary anteriors with resultant inc overjet.
- Patient exhibits convex profile.
- Having increased overbite & excessive curve of spee.
- Patient exhibits “Liptrap”
- Often lack lipseal.
- Patient exhibits abnormal muscle activity leading to constricted upper arch which predisposes to cross bite.

General clinical features of Class II division 2

Extra-Oral:

-Shape of the head: brachycephalic

-Facial profile: convex (striaght)

-Chin : Prominent

-Lower Lip: Everted (lower lip line is high relative to the upper incisors)

-Upper Lip: Positioned high in respect to the upper anterior (Gummy smile)

-Mentolabial sulcus: Deep

-Mentalis : Hyperactive

- ***Intra-Oral:***

- Class II molar relation (Distocclusion)

- Class II canine relation

- Retroclined maxillary central (extruded)

- Labialy tipped maxillary lateral incisors

- Deep bite: overclosure (closed bite)

- Decreased overjet

- Accentuated curve of Spee

- Retroclined lower incisors

(Extruded → lack of stops)

AETIOLOGY

- ***SKELETAL PATTERN***
- ***HABITS***
- ***SOFT TISSUES***
- ***DENTAL FACTORS***

Skeletal Class II malocclusion Results from a discrepancy in the maxillary-mandibular skeletal relationship. It might be either due to:

1) Mandibular deficiency

2) Maxillary excess

3) or a combination of both

Skeletal Class II → Mandibular deficiencyIt is a skeletal class II relationship resulting from a mandible that is either small or retruded relative to the maxilla.

- ***Mandibular deficiency due to small size of ramus and body of mandible. This results in a downward or backward rotation of mandible and this result in:***

Cephalometric Features

**** Decreased posterior facial height.***

**** Steeper mandibular plane angle.***

**** A normal SNA angle.***

**** Decreased SNB angle.***

**** Inceased ANB angle.***

**** Increased angle of convexity.***

**** Normal position of point A but a posterior positions of point B relative to Nasion perpendicular.***

**** It is common in a sever mandibular deficiency to have dental compensation for the skeletal disproportion displayed cephalometrically as protruded lower incisors (increased angulation of mandibular incisors relative to mandibular plane on Frankfort horizontal.***

- ***Class II div 2 with a small mandible→the decreased size is localized more to the mandibular body (Mandibular Ramus is of normal lenght)***

Cephalometrically:

1) Flat mandibular plane

2) Increasesd posterior facial height

3) Short lower anterior facial height

(resulting in both upper and lower lip having a more everted position at rest)

4) Mandibular length measured from Ar-Gn-Pog may appear normal because of the excessive chin projection.

5) SNA: normal , SNB: decreased , ANB: increased (Stiener)

- ***Mandibular deficiency may result from the retrusion (distal positioning) of a normal-sized mandible.***

Cephalometrically:

SNA: Normal , SNB: Decreased ,ANB: Increased (Stiener)

-Distinguishing characteristics:

a)The cranial base defined by (S-N-Basion) is more obtuse

b)Gleniod fossa in a relatively posterior in position.

c)Normal size of mandibular ramus and body

d) normal lower facial height

Skeletal Class II → Maxillary excess

1. ***Vertical dimension (Posterior excess ,0r Overall vertical excess)***
2. ***or Anterior-posterior dimension***
3. ***(Combination of both)***

- Vertical Maxillary excess may be localized only to the posterior area → Open bite and incompetent lips (normal vertical display of maxillary incisors in repose and during smiling.)

- Overall maxillary excess includes both the anterior and the posterior area → resulting in an excessive vertical display of the maxillary incisors in repose and during smiling (high smile line)→ Gummy smile.

- In these 2 conditions of maxillary excess→ Mandible is rotated downward and posteriorly (clockwise)→ resulting in a class II skeletal relationship.

- ***Class II with an overall vertical maxillary excess:***

Cephalometrically:

-SNA: Normal , -SNB: Decreased , -ANB: Increased (Stiener)

-Increased lower anterior facial height

-Steeper mandibular plane

-More inferior position of the maxillary molars relative to palatal plane.

-Clockwise rotation of the mandible

- ***Maxillary excess in Ant-Post Dimension is characterized by a protrusion of the entire midface including :***

  1. **Nose**
  2. **infraorbital area**
  3. **Upper lip**

Cephalometrically:

SNA: increased , SNB: Normal , ANB: Increased

-Increased face convexity. -Overjet: excessive

-Over eruption of mandibular incisors -Excessive overbite.

--If midface protrusion is severe →The lower lip will be positioned lingual to maxillary incisors encouraging there protrusion.

- **Skeletal Class II might be a combination of both mandibular deficiency and maxillary excess. Which will add to the severity of the Ant-post skeletal problem.**

- ***SOFT TISSUES FACTORS :- Influence of soft tissue is mainly mediated by skeletal pattern both antero-posteriorly & vertically.***

  - ***In a Class II division 1 malocclusion the lips are typically incompetent owing to the prominence of the upper incisors and/or the underlying skeletal pattern. If the lips are incompetent,***
  - ***Patient's try to achieve anterior oral seal in one of the following ways:***
    - ***Circumoral muscular activity.***
    - ***Forward postured mandible.***
    - ***Lower lip is drawn up behind the upper incisors.***
    - ***Tongue is placed forward between incisors to contact lower lip.***
    - ***Combination of these***

Where the patient can achieve lip-to-lip contact by circumoral muscle activity or the mandible is postured forwards, the influence of the soft tissues is often to moderate the effect of the underlying skeletal pattern by dento-alveolar compensation.

More commonly the lower lip functions by being drawn up behind the upper incisors, which leads to retroclination of the lower labial segment and/or proclination of the upper incisors with the result that the incisor relationship is more severe than the underlying skeletal pattern.

If the lower facial height is reduced

- ***A high lower lip line will tend to retrocline the upper incisors.***
- ***Class II division 2 incisor relationships may also result from bimaxillary retroclination caused by active muscular lips irrespective of the skeletal pattern..***

- ***HABITS FACTORS digit sucking lead to :-***
- ***Proclination of the upper incisors.***
- ***Retroclination of the lower labial segment.***
- ***Incomplete overbite or localized anterior open bite.***
- ***Narrowing of maxillary arch,Due to alteration in the balance between cheek & tongue pressure***

- ***Dental factors: The causes of dental Class II malocclusions can be subdivided into two groups:***

  1- Maxillary dental protrusion

  Maxillary dental protrusion may be confused with anteroposterior maxillary excess or midface protrusion, maxillary dental protrusion is not a skeletal problem but a dentoalveolar one that is limited to the maxillary dental arch. The facial appearance of anteroposterior maxillary excess is a protrusion of the entire midface, whereas maxillary dental protrusion only affects the lips. Excessive overjet is a reliable feature of this dental malocclusion, and there may be generalized maxillary spacing.

  2- Mesial drift of the maxillary first permanent molars.

  Mesial and occlusal drift of the permanent first molars occurs if there is loss of mesial proximal contact with the second primary molars from congenital absence, extraction, dental caries or ankylosis.

  Ectopic molar eruption, if left untreated, the maxillary first permanent molar assumes a more mesial position, resulting in a Class II permanent molar relationship if the mandibular arch is unaffected .

Factors influencing a definitive treatment plan

1-**Severity of malocclusion**

- The skeletal pattern is the major determinant of the difficulty of treatment.
- Those cases with a marked anteroposterior discrepancy and/ or significantly increased or reduced vertical skeletal proportions will require careful evaluation, an experienced orthodontist, and possibly surgery for a successful result

2) Age of the patient **Timing of the treatment:** is an important factor in the amount of change that can be produced

- Optimum time for growth modification→ Pre-pubertal growth spurt
- therefore proper diagnosis of the patient at early age and the use of correct functional appliances will cause the patient to → aviod surgery

3-The patient's facial appearance

- For example, in a case with a Class II skeletal pattern due to a retrusive mandible, a functional appliance may be preferable to distal movement of the upper buccal segments with headgear.
- The profile may also influence the decision whether or not to relieve mild crowding by extractions.
- Features include an obtuse nasolabial angle or excessive upper incisor show a surgical approach may be preferred

4-The likely stability of overjet reduction

- The soft tissues are the major determinant of stability following overjet reduction
- **Ideally, at the end of overjet reduction the lower lip should act on the incisal one-third of the upper incisors and be able to achieve a competent lip seal.**
- If this is not possible, consideration should be given as to whether treatment is necessary (if alignment is acceptable and the overjet is not significantly increased) and, if indicated, whether prolonged retention or even surgery is required.

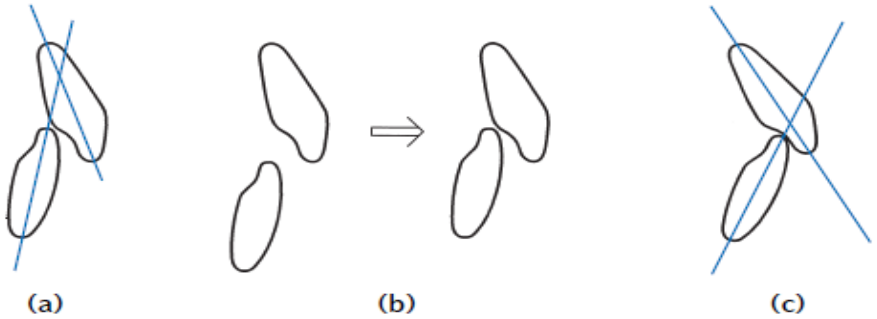

If a Class II division 2 incisor relationship is to be corrected not only the overbite but also the inter-incisal angle must be reduced to prevent re-eruption of the incisors post-treatment: (a) Class II division 2 incisor relationship; (b) reduction of the overbite alone will not be stable as the incisors will re-erupt following removal of appliances; (c) reduction of the inter-incisal angle in conjunction with reduction of the overbite has a greater chance of stability.

The inter-incisal angle in a Class II division 2 malocclusion can be reduced in a number of ways:

- Torquing the incisor roots palatally/lingually with a fixed appliance
- Proclination of the lower labial segment. This approach should only be employed by the experienced practitioner as, although it provides additional space for alignment of the lower incisor teeth, any excessive movement of the lower arch would increase the risk of relapse.
- Proclination of the upper labial segment followed by use of a functional appliance to reduce the resultant overjet and achieve intermaxillary correction.
- A combination of the above approaches.
- Orthognathic surgery. This approach may be the only alternative for patients with a marked Class II skeletal pattern and/or reduced vertical skeletal proportions.

Treatment of Class II

- **Class II malocclusion → Dental or Skeletal**

Dental Class II → Orthodontic treatment (extraction or non extraction)

Skeletal Class II →

1) Growth modification (Growing patient)

2) Dental camouflage (extraction vs non extraction)

(mild to moderate skeletal class II)

3) Orthognathic surgey + with orthodontic treatment

(moderate to severe Class II)

For a dental Class II malocclusion:

Extraction or non-extraction treatment.→ depending on the severity of mesial drift of the maxillary 1st molar.

-slight mesial drift (mesial crown tipping) + minimal crowding → Nonextraction + distalization of maxillary 1st molar

- severe mesial drift (roots and crown are mesially positioned) → extraction is indicated to obtain space**.**

Treatment of skeletal Class II malocclusion

- **Growth modification for class II skeletal problem: (Orthopedic treatment)**

- the goal of growth modification is to enhance the unacceptable skeletal relationship by modifying remaining facial growth pattern of the jaws.

- Optimum timing : Pre-pubertal growth spurt *(active growth period)*

Type :- I) Headgear (extra-oral force)

2) Functional appliances (Removable and fixed)

- Headgear:

it delivers an extra-oral orthopedic force to compress the maxillary sutures and modify the pattern of bone apposition at these sites as well as distalize the maxillary dentition or maxilla itself. It derives the anchorage from cervical or cranial regions.

The goal of treatment is to restrict the maxillary growth, while the mandible continues to grow forward to forward to “catch up” the maxilla

Components of Head gear:

-1) Face bow:- It is a metallic component that helps in transmitting extra oral forces on to the posterior teeth. It consists of outer bow, inner bow & junction.

2) Force element:- It provides the force to bring about desired effect comprises of springs, elastics & stretchable materials.

3) Head cap or Cervical strap:- The appliance takes anchorage by means of head cap or cervical strap.

- Functional appliances: Class II functional appliances are designed to position the mandible in a downward and forward to enhance its mandibular growth pattern.
- Indication: Mandibular deficiency

Removable Functional:	**Fixed Functional:**
-Activator	-Herbst
- Bionator	-Jasper jumper
-Twin blocK	
- Frankyl II	

Dental Camouflage:

- It is a treatment that seeks to create a dental compensation to hide the skeletal discrepancy → Maxillary Retroclination and Mandibular Protraction.
- ***Indicated:***

1. Adults
2. Mild to Moderate skeletal Class II cases
3. Minimal dental crowding .
4. Acceptable facial esthetics
5. Usually requires extraction

Orthognathic surgery:

- A combination of orthodontic therapy and Orthognathic surgery for the correction of moderate to severe skeletal class II malocclusion *(Adults, no growth potential)*

- Indicated:

    1) Moderate to Severe skeletal discrepancy
    2) Facial imbalances or asymmetries: long lower face , Gummy smile
    3) Limitations of tooth movement : Upright on basal bone
    4) Relapse potential of orthodontic treatment.
    5) Severe crowding and protrusion in the dental arches with skeletal class II malocclusion (extraction space is not sufficient to correct buccal occlusion)

- Surgical correction includes:

1) Mandibular Advancment: skeletal class II cases with mandibular deficiency

The intraoral sagittal split ramus osteotomy is the most popular technique for surgical mandibular advancment.

2)Maxillary Impaction: (Le Fort 1 maxillary osteotomy)

Indicated: Vertical Maxillary excess ,

Vertical maxillary excess in the anterior and posterior region of maxilla

→ Requires maxillary impaction by a total maxillary ostoetomy .

To correct the:

1) Gummy smile
2) Excessive lower facial height
3) Incompetent lips
4) Mandible will rotate anti-clock wise

3)Anterior Maxillary sub-apical setback

Indicated: Maxillary excess is in A-P dimension/ Mid-face protrusion (No vertical excess)

- **Combined Surgical approaches :**

Indicated: Maxillary excess (vertical or A-P) combined with mandibular deficiency.

Refrences

-An Introduction to Orthodontic.fourth edition 2013 United Kingdom--Laura Mitchell, MBE Oxford

-CONTEMPORARY ORTHODONTICS , FifTH EDITION 2013--WILLIAM R. PROFFIT, MOSBY

--Textbook of Orthodontics Second Edition: 2007--Gurkeerat Singh, Jaypee New Delhi 110 002, India

--ORTHODONTIC REVIEW, SECOND EDITION 2015--Jeryl D. Sercan Akyalcin -Timo Peltomäki -Kate Litschel, by Mosby, an imprint of Elsevier Inc

MANAGEMENT OF CLASS I MALOCCLUSION

" Occlusion is the relationship of the maxillary and mandibular teeth when the jaws are in fully closed position.

A Class I incisor relationship is defined by the British Standards incisor classification as follows: 'the lower incisor edges occlude with or lie immediately below the cingulum plateau of the upper central incisors.

Therefore Class I malocclusions include those where the anteroposterior occlusal relationship is normal and there is a discrepancy either within the arches and/or in the transverse or vertical relationship between the arches

- Approximately ***60%-70%*** of all cases of malocclusion fall into this class

LINE OF OCCLUSION

- FOR UPPER ARCH : **Smooth curve passing through the central fossa of each upper molar and across the cingulum of upper canine and incisor teeth.**
- FOR LOWER ARCH: **The same line runs along the buccal cusp and incisal dges of lower teeth.**

Features of class I malocclusion

- **Harmonious face**
- **Straight to convex profile**
- **Lip competence is dependant on degree of anterior proclination**
- **Class I relationship of the molars, canine& incisor but line of occlusion incorrect**
- **Individual tooth malocclusion with varying degree of severity**
- **Malocclusion may be in vertical and transverse planes.**

***class I malocclusion* include:-**

- **openbite**
- **Deep bite**
- **Bi-maxillary protrusion**
- **Crossbite**
- **Malposed teeth**
- **Rotations**
- **Spacing of teeth**
- **Crowding**

CAUSES OF CLASS I MALOCCLUSION

- **DEVELOPMENTA** INCLUDES:
  - **Supernumerary teeth.**
  - **Impacted teeth**
  - **Ectopic eruption**
  - **Congenitally missing teeth.**
  - **Malformed teeth.**

- **GENETIC Plays major role for malocclusion where there is discrepancy between the size of jaws and size of teeth.**
- **ENVIRONMENTAL CAUSED BY Injuries which has two types:**

- **BIRTH INJURIES: Trauma during birth from usage of forceps.**
- **INJURIES THROUGHOUT LIFE: trauma to teeth can lead to:**
  - **Damage to permanent tooth bud.**
  - **Premature loss of primary teeth leads to permanent tooth movement.**
  - **Direct injury to permanent teeth.**

- In Class I malocclusions the skeletal pattern is usually Class I, but it can also be Class II or Class III with the inclination of the incisors compensating for the underlying skeletal discrepancy i.e. dento-alveolar compensation.
- In most Class I cases the soft tissue environment is favourable and is not an aetiological factor.
- The major exception to this is bimaxillary proclination, where the upper and lower incisors are proclined. This may be racial in origin and can also occur because lack of lip tonicity results in the incisors being moulded forwards under tongue pressure

MANAGEMENT OF CLASS I MALOCCLUSION

CROWDING: **'Is defined as malalignment of teeth caused by inadequate space.'**

- **Occurs due to GENETIC or ENVIRONMENTAL factors.**

Those teeth that erupt last in segment, e.g. lateral incisors, upper canines, 2nd premolars, 3rdmolars are most commonly affected

there are different methods of classification of crowding

Classified according to the etiology

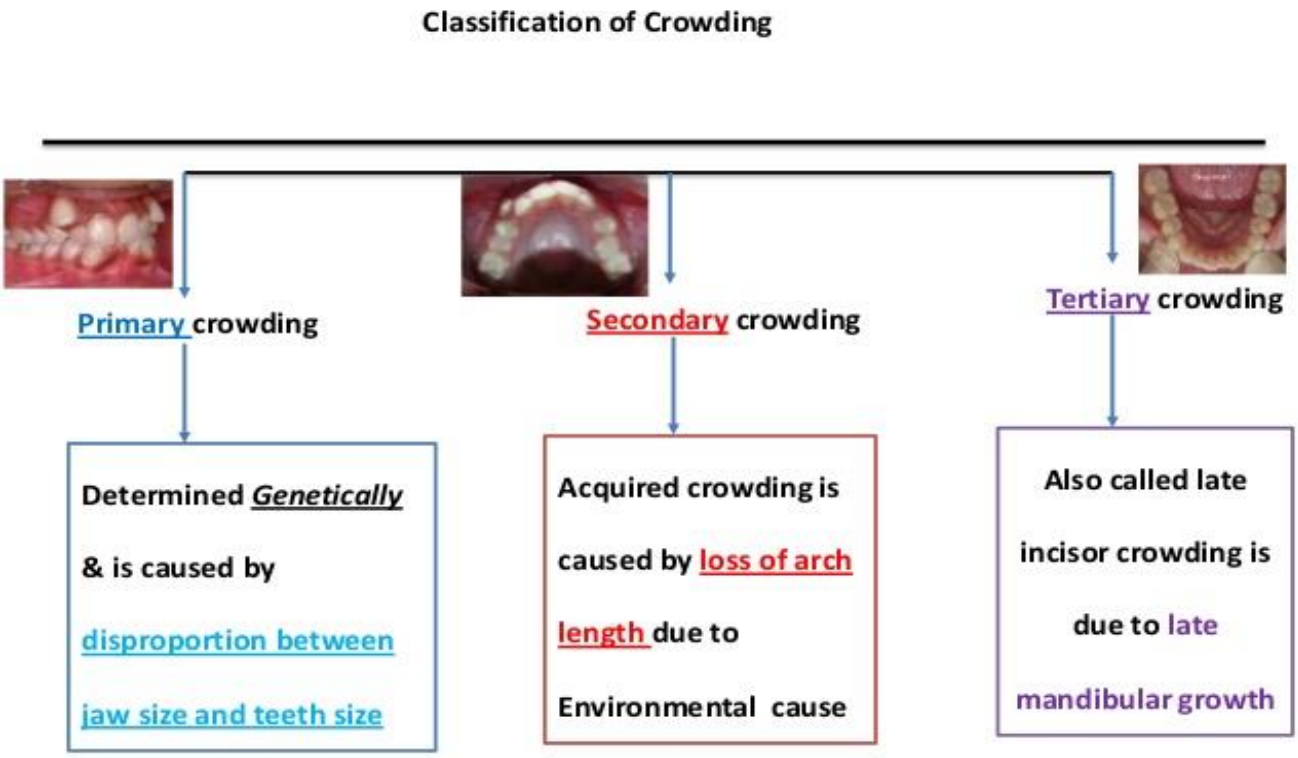

Classified according to the severity as:

- **Mild crowding --- less than 4mm per arch.**
- **Moderate crowding --- 5 to 9mm per arch.**
- **Severe crowding --- 10mm or more per arch.**

Before carrying out treatment,the following aspects should be considered:

- **Degree of crowding.**
- **Site and position of crowding.**
- **Patient's age.**

Treatment of Crowding

1.Mild crowding: accepted or Usually resolves without extraction

- -Proximal stripping
- Arch expansion ,
- -Molar distalization

2. Moderate crowding:

- -Enamel reduction.
- Or by extractions
- -Arch expansion ,
- -Molar distalization

3. Severe crowding: -Extraction of first premolars

A degree of natural spontaneous movement will take place. In general, this is greater under the following conditions:

- in a growing child;
- if the extractions are carried out just prior to eruption of the adjacent teeth;
- where the adjacent teeth are favourably positioned to upright if space is made available (for example considerable improvement will often occur in a crowded lower labial segment provided that the mandibular canines are mesially inclined);
- there are no occlusal interferences with the anticipated tooth movement

SPACING: **'Gaps between two teeth or many teeth' Can be:**

- **Localized (space present in localized regions or areas)**
- **Generalized (space present in entire arch)**

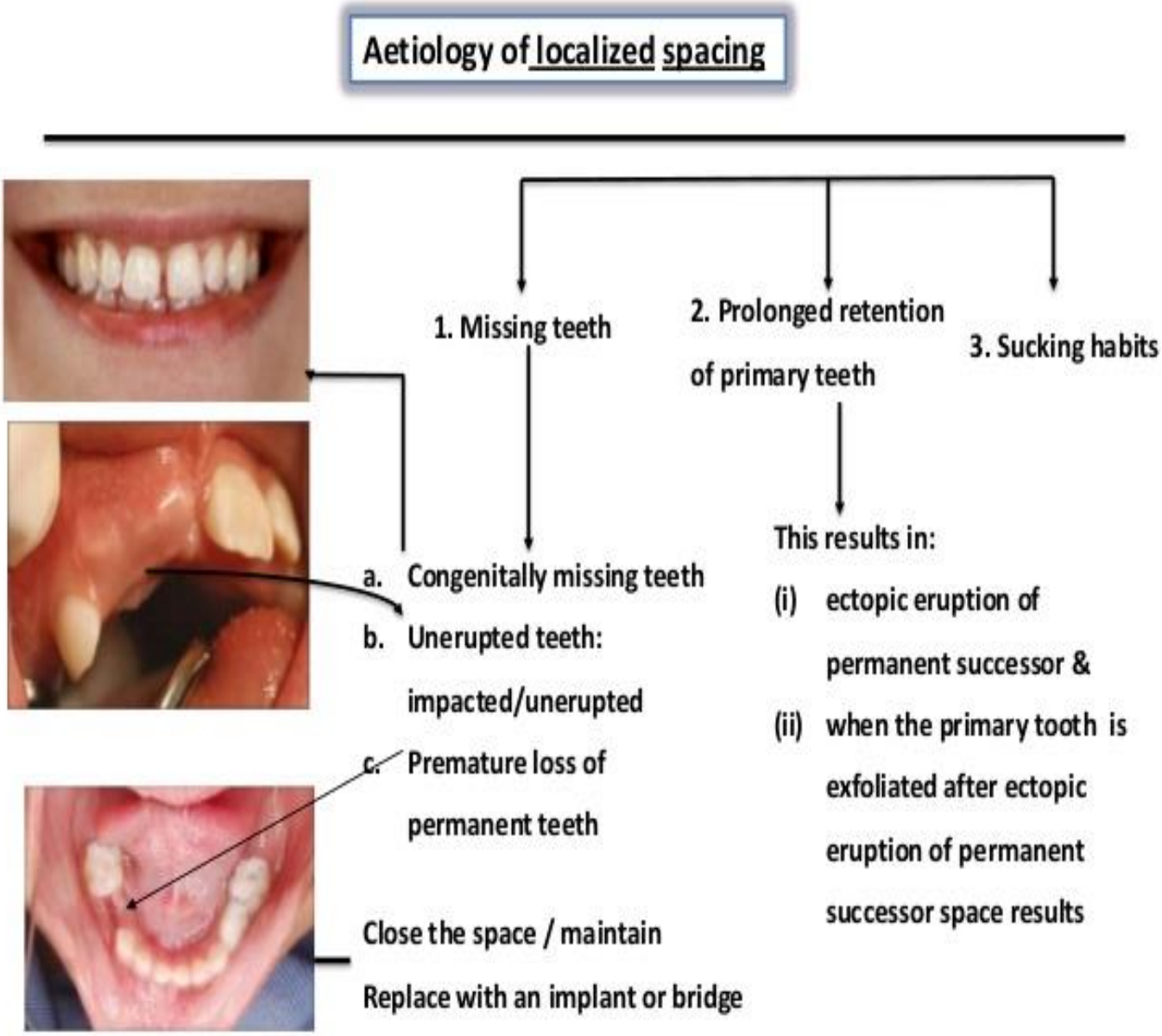

Median diastema

Is a form of localised spacing wherein there is a space present b/w two central incisors

Causes of median diastema

- Normal/developmental
  1. Physiological median diastema
  2. Ethnic & familial
  3. Imperfect fusion at midline of premaxilla
- Tooth material discrepancy
  1. Micodontia
  2. Macrognathia
  3. Missing lateral
  4. Peg lateral
  5. Extracted teeth
- Physical impediment
  1. Retained deciduous
  2. Mesiodens
  3. Enlarged labial frenum
  4. Midline pathology
- Habits
  1. Thumb sucking
  2. Tongue thrusting
- Artificial causes
  - RME

MANAGEMENT

a) REMOVAL OF CAUSE

DIASTEMA DUE TO RETAINED DECIDUOS TEETH/MESIODENS

The retained deciduous tooth or mesiodens should be extracted at the earliest.

DIASTEMA DUE TO ABNORMAL FRENUM

Frenectomy should be done to excise a thick fleshy frenum.

DIASTEMA DUE TO MIDLINE PATHOLOGY

Midline pathology like cysts has to be treated.

DIASTEMA DUE TO ABNORMAL HABITS

Habits should be eliminated using fixed or removable habit breakers.

b) ACTIVE TREATMENT

- , Closure of a midline diastema can be accomplished with a removable appliance and finger springs to tip the teeth mesially.
- Closure by bodily movement using a Fixed appliances incorporating elastics and springs bring about the most rapid correction of midline diastema
- Closure by reduction of over jet if the space result from proclination of incisors

- Restorative mangment, Esthetic composite resins are used to close midline diastema especially in adult patients.

c) RETENTION Midline diastema is often considered easy to treat but difficult to retain. Retention can be achieved by Lingual bonded retainers or Hawley's retainer

GENERALIZED SPACING

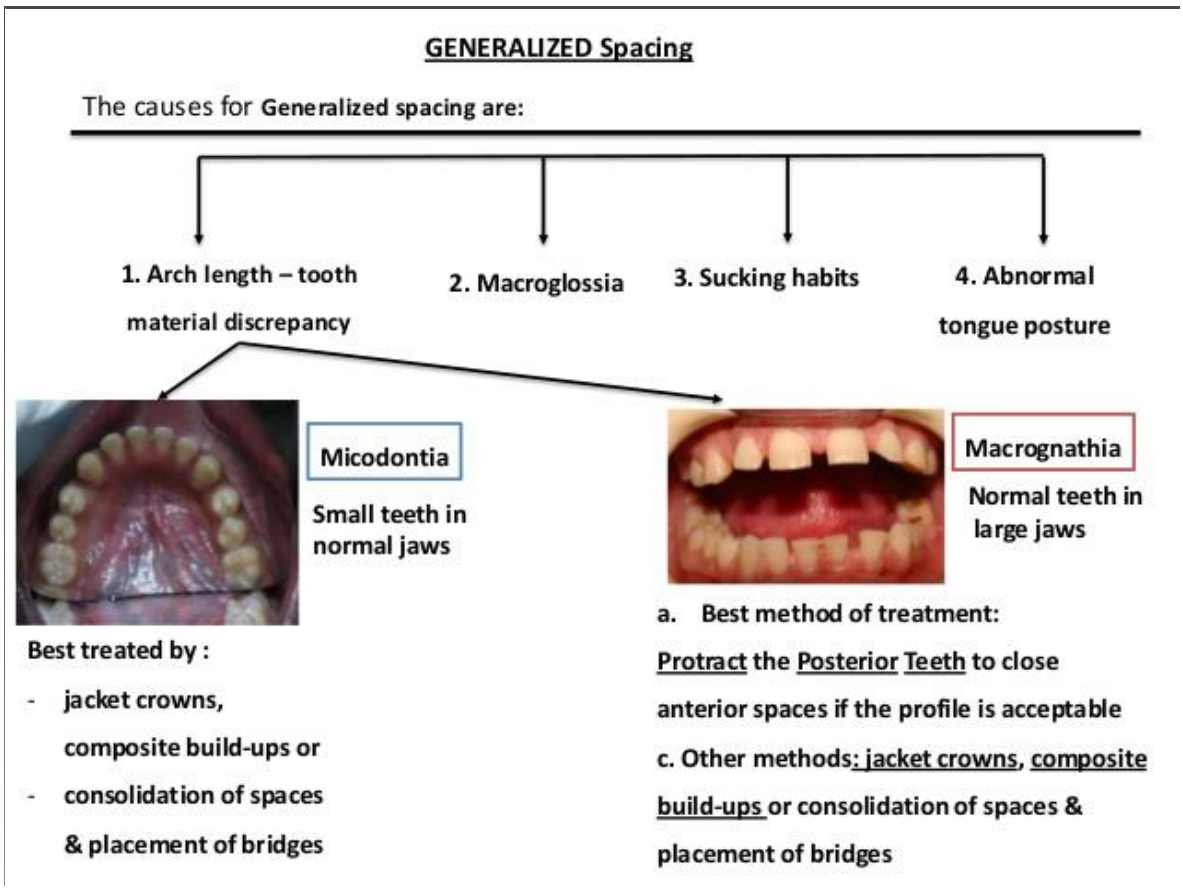

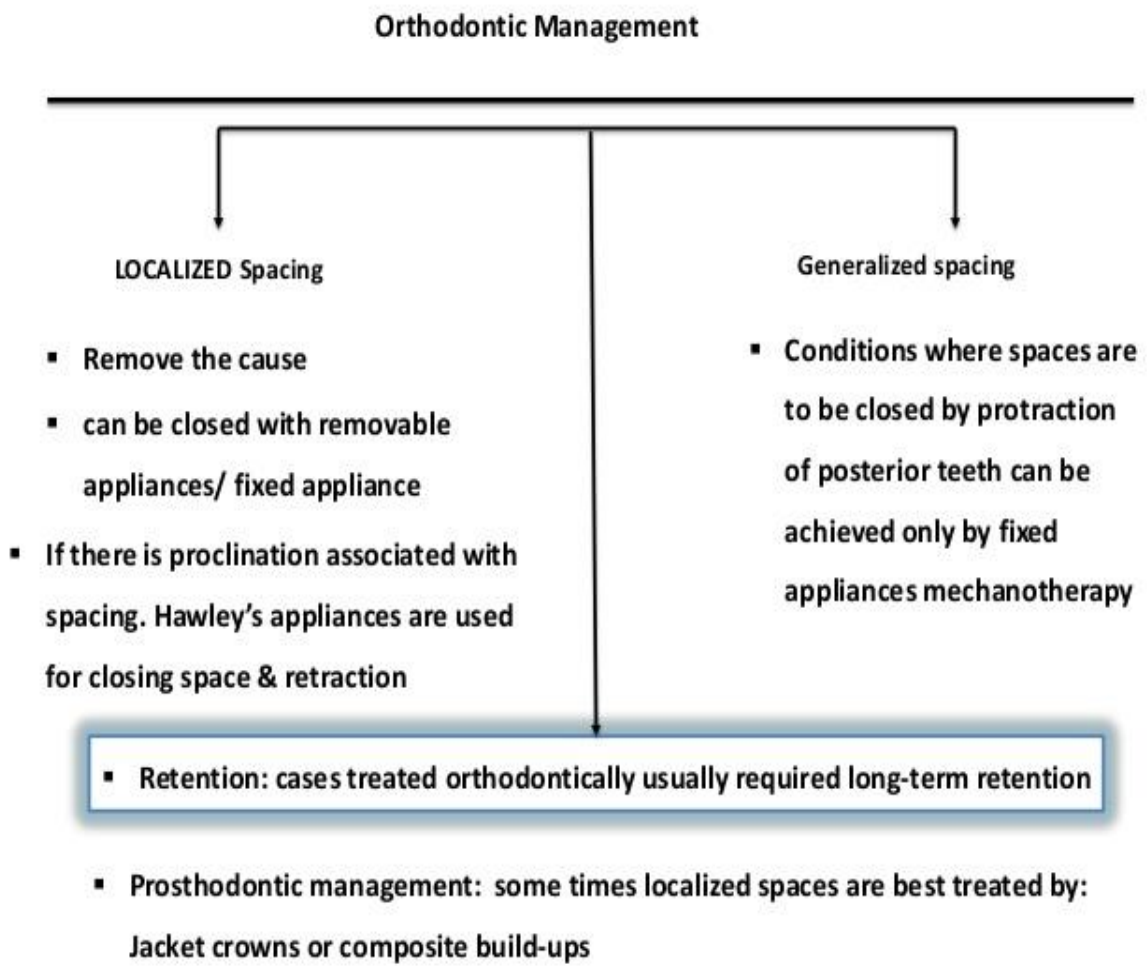

- **Orthodontic management of generalized spacing is frequently difficult as there is usually a tendency for the spaces to reopen unless permanently retained**
- **In milder cases it may be wiser to encourage the patient to accept the spacing,**

IN CASE OF MICRODONTIA

- **if the teeth are narrower than average, acid-etch composite additions or porcelain veneers can be used to widen them and thus improve aesthetics.**
- **or : Eliminate spaces between anteriors, leaving a space between canine and 1st premolar& Give prosthesis or implant.**

<u>BIMAXILLARY PROTRUSION</u>: The patient exhibits a normal class I molar relationship but the dentition of both the upper and lower arches are forwardly placed in relation to facial profile

<u>EXTRAORAL FEATURES</u>

- **Decreased nasolabial angle due to proclined maxillary anteriors**
- **Shallow mentolabial sulcus due to proclined mandibular anteriors.**
- **Lips may be incompetent**
- **Convex facial profile**

<u>INTRAORAL FREATUES</u>

- **Class I canine relationship (may be)**
- **Spacing between teeth. (may be)**
- **Maxillary and mandibular anterior proclination.**
- **Class I molar relationship**

<u>CEPHALOMATRIC FINDINGS</u>

- **Decreased interincisal angle**
- **Increased incisor mandibular plane angle**
- **Increased SNA and SNB, if there is prognathism of jaws.**

- Management is difficult because both upper and lower incisors need to be retroclined.
- Retroclination of the lower labial segment will encroach on tongue space and therefore has a high likelihood of relapse following removal of appliances

- For these reasons, treatment of bimaxillary proclination should be approached with caution and consideration should be given to accepting the incisor relationship.
- If the lips are incompetent, but have a good muscle tone and are likely to achieve a lip-to-lip seal if the incisors are retracted, the chances of a stable result are increased.
- Where bimaxillary proclination is associated with competent lips, or with grossly incompetent lips which are unlikely to retain the corrected incisor position, it may be wiser not to proceed.
- However, if treatment is decided upon, permanent retention is advisable.

Refrences

-An Introduction to Orthodontic.fourth edition 2013 United Kingdom--Laura Mitchell, MBE Oxford

-CONTEMPORARY ORTHODONTICS , FifTH EDITION 2013--WILLIAM R. PROFFIT, MOSBY

--Textbook of Orthodontics Second Edition: 2007--Gurkeerat Singh, Jaypee New Delhi 110 002, India

--ORTHODONTIC REVIEW, SECOND EDITION 2015--Jeryl D. Sercan Akyalcin -Timo Peltomäki -Kate Litschel, by Mosby, an imprint of Elsevier Inc

Cleft lip and palate

- **PREVALENCE**

Cleft lip and palate is the most common craniofacial malformation, comprising 65 per cent of all anomalies affecting the head and neck. There are two distinct types of cleft anomaly, cleft lip with or without cleft palate and isolated cleft palate, which result from failure of fusion at two different stages of dentofacial development

Cleft lip and palate

- **Amongst Caucasians, this anomaly occurs in approximately 1 in every 750 live births.**
- **. A family history can be found in around 40 per cent of cases of cleft lip with or without cleft palate, and the risk of unaffected parents having another child with this anomaly is 1 in 20.**
- **Males are affected more frequently than females, and**
- **the left side is involved more commonly than the right**

Isolated cleft of the secondary palate

- **occurs in around 1 in 2000 live births**
- **and affects females more often than males.**
- **Clefts of the secondary palate have a lesser genetic component, with a family history in around 20 per cent and a reduced risk of further affected offspring to normal parents (1 in 80).**
- **Isolated cleft palate is also found as a feature in a number of syndromes including Down, Treacher–Collins**
- **Clefting of the *lip* occurs because of a failure of fusion between the median and lateral nasal processes and the maxillary prominence, which normally occurs in humans during the *sixth week* of development**

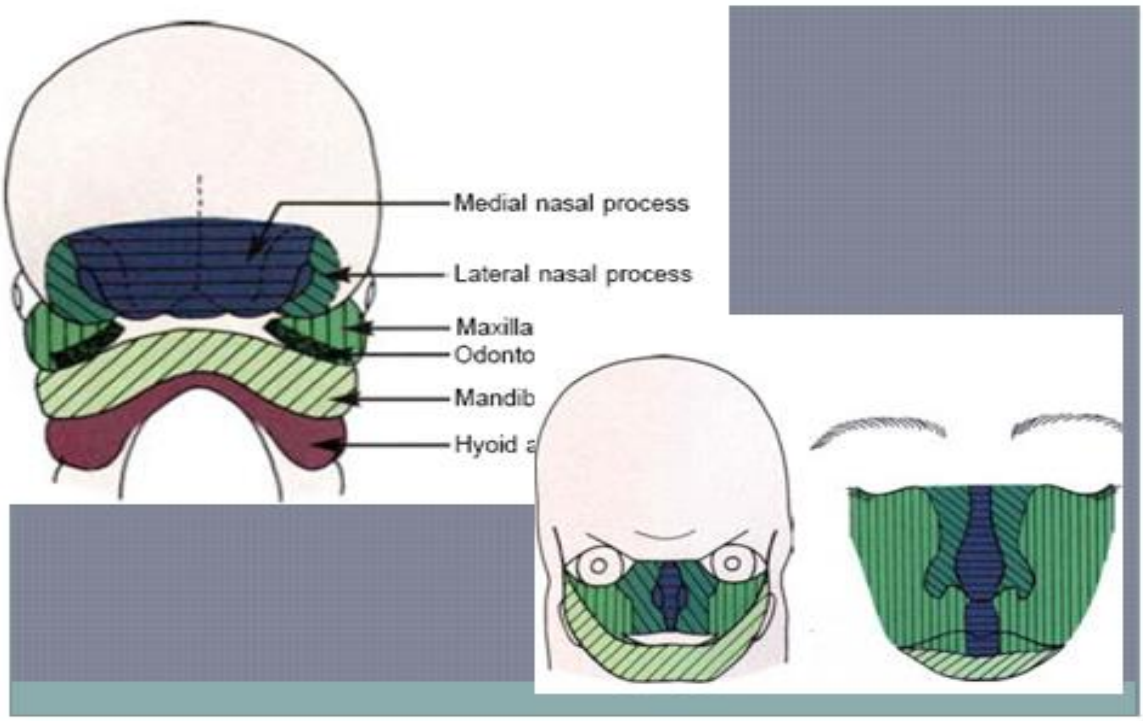

- **Closure of the secondary palate by elevation of the palatal shelves follows that of the primary palate by nearly 2 weeks, which means that an interference with lip closure that still is present can also affect the palate.**
- **About 60% of individuals with a cleft lip also have a palatal cleft.**
- **An isolated cleft of the secondary palate is the result of a problem that arose after lip closure was completed.**
- **Incomplete fusion of the secondary palate, which produces a notch in its posterior extent (sometimes only a bifid uvula), indicates a very late-appearing interference with fusion.**
- **Delayed elevation of the palatal shelves from the vertical to the horizontal while the head is growing continuously results in a widening gap between the shelves so that they cannot meet and therefore cannot fuse. This leads to clefting of the palate when they eventually do become horizontal.**
- **Other causes of cleft palate are defective shelf fusion, failure of medial-edge epithelial cell death, possible postfusion rupture, and failure of mesenchymal consolidation and differentiation.**

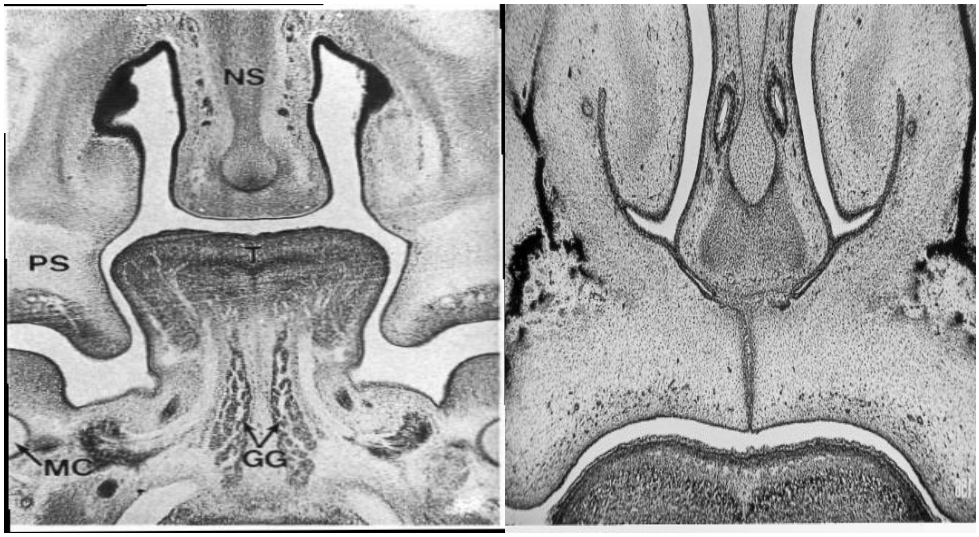

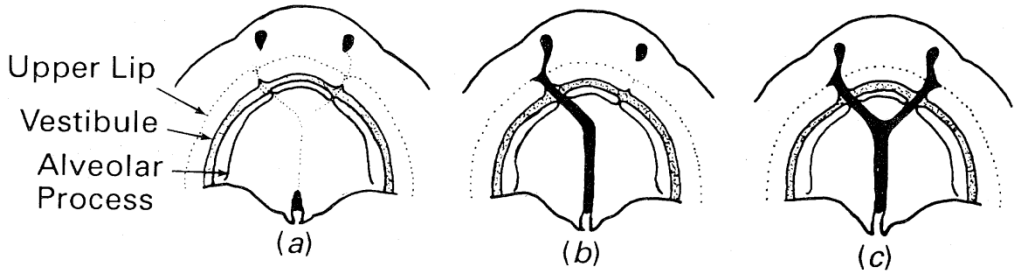

Variations in palatal clefting: (*a*) bifid uvula; (*b*) unilateral cleft palate and lip; (*c*) bilateral cleft palate and lip.

Multifactorial Threshold Hypothesis

Multifactorial inheritance theory implies that many contributory risk genes interact with one another and the environment and collectively determine whether the threshold of abnormalities is reached, resulting in a defect in the developing fetus

Environmental factors for example

- **Infections Infections like Rubella, Influenza, Toxoplasmosis, etc. to the mother during pregnancy may cause formation of the defct in the fetus.**
- **drugs : anticonvulsant drugs, folic acid deficiency, or steroid therapy, hypervitaminosis and**
- **radiations**

PROBLEMS ASSOCIATED WITH CLEFT LIP AND PALATE

- **PSYCHOLOGICAL**

The disfigurement caused by the condition is enough to cause psychological stress for the patient and the family.

- **ESTHETIC**

The patients with un-repaired clefts are badly disfigured due to the nature of the deformity. Even following the closure of the cleft the maxilla remains underdeveloped and the patient usually has a Class III skeletal profile with compromised esthetics

- **SPEECH AND HEARING**

Cleft lip and palate have definite speech problems. These are sometimes associated with infections of the middle ear. Since speech is learnt by the art of imitation, if hearing is compromised so is the speech.

- **DENTAL**

➢ **The clefts are generally associated with underdeveloped maxilla and associated structures. The patient may present with some of the following features:**

- **Multiple missing teeth (most commonly the maxillary lateral incisors).**
- **Mobile premaxilla.**
- **Anterior and / or posterior cross bites.**
- **Ectopically erupting teeth.**
- **Impacted teeth.**
- **Supernumeraries.**
- **Poor alignment often predisposes to poor oral hygiene.**
- **Multiple decayed teeth.**
- **Periodontal complications.**

MANAGEMENT OF CLEFT LIP AND PALATE

The management of cleft cases requires team work :-

- **orthodontist**
- **maxillofacial surgeon**
- **plastic surgeon**
- **speech therapist**
- **ear, nose, and throat (ENT) surgeon.**
- **health visitor**

Stage I

- **The first stage extends from birth to 24 months. The orthodontist may be called upon to perform the following two functions:**
- **Fabrication of a feeding plate or passive maxillary obturator.**
- **Strapping of the premaxilla or other infant orthopedic procedures**

<u>Infant Orthopedics</u>

An infant with a cleft lip and palate will have a distorted maxillary arch at birth

Types of movement of the maxillary segments **:**

1. ***The collapsed maxillary posterior segments must be expanded laterally.***
2. ***Pressure against the premaxilla can reposition it posteriorly into its approximately correct position in the arch.***

If presurgical movement of maxillary segments is indicated, this typically would be done at the beginning of 3 to 6 weeks of age .

- **Surgical correction of Lip is done in early infancy as it is compatible with a good long-term result.**
- **The common guidelines (as advocated by Millard) is age 10 weeks, weight 10 pounds and hemoglobin 10 gm%**

- **An intact palate aids the acquisition of normal speech. At this time speech is developing rapidly.**
- **For ideal speech, therefore palate closure between the age of 12 and 24 months is recommended.**
- **Some authors prefer to wait and recommend palatal repair in the age group of 9 to 12 years.**

Stage II

- **This stage extends from 24 months to 6 years of age.**
- **The period covers the primary dentition. The orthodontist plays the part of an observer and monitors the development of the dentition.**
- **Generally no active orthodontic treatment is undertaken during this stage**
- **The oral-hygiene instruction may be emphasized upon and procedures undertaken to preserve the existing tooth structures.**

Stage III

This stage extends from 6 to 12 years of age, i.e. the mixed dentition stage. The orthodontist plays a major role during this stage.

• Arch expansion can be undertaken.

• Maxillary protraction devices can be made use of.

• Fixed orthodontic treatment can be initiated, which will form the basis of the final alignment and position of the teeth.

- **The patient is referred for a bone graft in the palatal region, before the eruption of the permanent maxillary canine.**
- **If the canine can be made to erupt through the graft, it adds to its stability.**

Stage IV

- **This stage corresponds to the permanent dentition and final corrections are made during this stage.**
- **A reasonable amount of alignment along with esthetics should be achieved.**
- **The canine, if not erupted is exposed and brought into alignment.**
- **The arches are aligned and the occlusion made to settle**
- **Planning is done regarding the need for orthognathic surgery. Consultation with the oral and maxillofacial and plastic surgeons is a must.**

The retention planned should be permanent in nature. Prosthetic rehabilitation can be accommodated in the retention appliance- using fixed bridges or cast partial dentures

Orthognathic Surgery for Patients with Cleft Lip and Palate

- **Continued mandibular growth after the completion of active orthodontic treatment leads to the return of anterior and lateral crossbites.**
- **This result is not so much from excessive mandibular growth as from deficient maxillary growth, both anteroposteriorly and vertically .**
- **Orthognathic surgery to bring the deficient maxilla downward and forward may be a necessary last stage in treatment .**

Refrences

-An Introduction to Orthodontic.fourth edition 2013 United Kingdom--Laura Mitchell, MBE Oxford

-CONTEMPORARY ORTHODONTICS , FifTH EDITION 2013--WILLIAM R. PROFFIT, MOSBY

--Textbook of Orthodontics Second Edition: 2007--Gurkeerat Singh, Jaypee New Delhi 110 002, India

--ORTHODONTIC REVIEW, SECOND EDITION 2015--Jeryl D. Sercan Akyalcin -Timo Peltomäki -Kate Litschel, by Mosby, an imprint of Elsevier Inc

Ortho.Lec.4 2019/2020 5th class Lecturer Zainab Bahgat

Treatment of crossbite

- **The first step in the management of crossbite is elimination of the factors that may lead to the cross bite E.g.**

- **Removal of occlusal prematurities.**
- **Extraction of supernumerary tooth, before they cause displacement of other tooth.**
- **Habit breaking appliance.**
- **Referring the patient with breathing problem to ENT specialist**

Depending upon the age of the patient, the eruption status of the teeth and the space availability various appliances have been designed to correct anterior cross bites

CORRECTION OF ANTERIOR CROSS BITE IN THE PREADOLESCENT AGE GROUP

1. Use of Tongue Blade

A tongue blade resembles a flat ice-cream stick.Used when a cross bite is seen at the time the permanent teeth are making an appearance in the oral cavity.

- **It is placed inside the mouth contacting the palatal aspect of the maxillary teeth.**
- **Upon slight closure of jaw the opposing side of the stick come in contact with the labial aspect of the opposing mandibular tooth acts as a fulcrum.**
- **Only effective till the clinical crown not completely erupted in the oral cavity.**
- **Used only if sufficient space is available for the correction.**
- **Patients cooperation is required.**

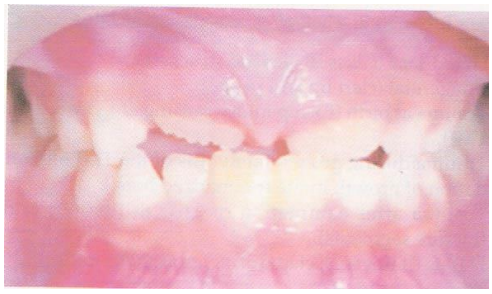

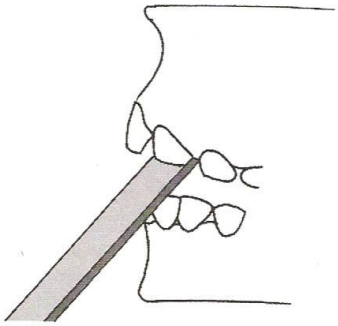

This is continued for 1-2 hours for about 2 weeks

[2] Double cantilever spring / z-spring

- **Is one of the most frequently used appliance to correct anterior tooth/ teeth cross bites.**
- **Effective only when there is enough space for aligning the teeth.**

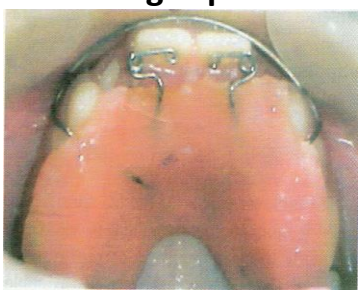

(3) Screw appliance

Acrylic appliances incorporating various size screws can be used to correct either individual tooth or segmental cross bites.

- ***Micro screw* are the most comfortable for the patient and can be used on individual teeth. Multiple micro-screws can be used to correct individual teeth in a segmental cross bite.**
- ***Mini-screws* are also used for the same purpose but are capable of moving up to two teeth.**
- ***Medium screws* are used to correct segmental cross bites. They are larger and are capable of moving 4-6 teeth in a segment.**
- ***3-D (three dimensional) screws* are capable of correcting posterior as well as anterior cross bites simultaneously. Appliances incorporating a 3-D screw, achieve an overall increase in the circumference of the maxillary arch. They are ideal to treat the anterior cross bites associated with pseudo-Class III malocclusions**
- **Generally, one full turn of the screw brings about 0.8 or 1 mm expansion that is one fourth turn would bring about 0.2/0.25 mm expansion.**

[4] Face mask (or face mask along with RME)

Used to correct skeletal anterior cross bite (Anterior cross bite due to actual skeletal deficiency of the maxilla)

[5] Chin cap appliance

Used to correct or prevent the anterior cross bite due to a prominent mandible.

- **Chin cap appliance rotate mandible backward and downward.**

[6] Frankel III appliance Used to correct skeletal class III Malocclusion.

The following factors should be considered in treatment of anterior crossbite

- **What type of movement is required? If tipping movements will suffice, a removable appliance can be considered, however, if bodily or apical movement is required then fixed appliances are indicated.**
- **How much overbite is expected at the end of treatment? For treatment to be successful there must be some overbite present to retain the corrected incisor position. However, when planning treatment it should be remembered that proclination of an upper incisor will result in a reduction of overbite compared with the pretreatment position.**
- **Is there space available within the arch to accommodate the tooth/teeth to be moved? If not, are extractions required and if so which teeth?**
- **Is movement of the opposing tooth/teeth required? If reciprocal movement is required, a fixed appliance is indicated**

Provided that there is sufficient overbite and tilting movements will suffice, treatment can often be accomplished with a removable appliance. The appliance should incorporate the following features:-

- **good anterior retention to counteract the displacing effect of the active element (where two or more teeth are to be proclined, a screw appliance may circumvent this problem);**
- **buccal capping just thick enough to free the occlusion with the opposing arch (if the overbite is significantly increased a flat anterior bite-plane may be utilized instead);**
- **an active element, for example a Z-spring.**

Fixed appliances are indicated in the following cases:

- **The apex of the incisor in crossbite is palatally positioned.**
- **If there will be insufficient overbite to retain the corrected incisor(s), consideration should be given to using fixed appliances to move the lower incisor(s) lingually at the same time as the upper incisor(s) is moved labially in order to try and increase overbite.**
- **Other features of a malocclusion necessitate the use of fixed appliances**

MANAGEMENT of posterior crossbite

Treatment plan considerations

- **Skeletal and dental contribution to crossbite.**
- **Age of the patient**
- **Functional contribution to crossbite.**

Rationale for early treatment

Posterior crossbite should be treated as early as possible even in the primary dentition.

- **Early correction will eliminate mandibular shift on closure and reduce the possibility of mandibular skeletal asymmetry(asymmetric mandibuiar growth).**
- **Research has shown that displacing contacts may predispose towards temporomandibular joint dysfunction syndrome in a susceptible individual**
- **Correcting posterior crossbite in the mixed dentition increases arch circumference and provides more room for the permanent teeth to erup.**
- **Reduces dental arch distortion.**

The various treatment modalities for posterior crossbite are :-

1) **Occlusal equilibrium.**
2) **Coffin spring.**
3) **Cross elastics.**
4) **Soldered W –arch (Porter appliance).**
5) **Quad Helix.**
6) **Removable appliance.**
7) **Rapid maxillary expansion (RME).**
8) **Ni-Ti expanders.**
9) **Oral screening.**
10) **Fixed orthodontic appliances.**

Unilateral crossbite

- **For crossbite correction of a premolar or molar, consider the use of a T -spring or screw section, respectively, on an URA**
- **If reciprocal movement of opposing teeth is required, use fixed attachments and cross elastics.,**
- **or extraction of a tooth in crossbite if there is more marked displacemen**
- **For correction of unilateral buccal segment crossbite associated with a mandibular displacement, use an URA with a midline expansion screw and buccal capping or quadhelix, provided teeth are not tilted buccally**

Correction of <u>true unilateral crossbite</u>

- **These are treated by asymmetric expansion of upper arch to move teeth on the constricted side. Asymmetric W arch with different length arms. The side of the**

arch to be expanded has fewer teeth than the anchorage unit. However, some bilateral expansion must be expected.

- **In adult if there is unilateral buccal segment crossbite with no mandibular displacement, as there is no functional problem, correction is not usually indicated unless it is part of a more comprehensive treatment**

Bilateral posterior crossbite

- **Skeletal maxillary constriction is characterized by a narrow palatal vault and can be corrected by opening the midpalatal suture.**
- **Like all craniofacial surures the midpalatal suture becomes more tortuous and interdigitated with increasing age.**
- **In children up to 9 or 10 years (skeletal age) expansion of suture is easy and can be accomplished with almost any type of expansion device.**
- **Split-plate removable appliance with expansion screw can be used for primary or mixed dentition child and will produce some opening of the midpalatal suture in addition to dental expansion, this type depends on patient compliance**
- **Lingual arch either of W arch or quad helix design. Both produce slow expansion and deliver a force of few hundreds grams and produce both skeletal and dental expansion.**
- **Heavy forces and rapid expansion are not indicated in young children, since there is significant risk of distortion of nose**
- **By adolescence the interdigitation of the suture has reached the point that a rigid expansion screw with considerable force is required to create micro fractures before the suture can open.**
- **Rapid maxillary expansion of the midpalatal suture can be tried, but no later than early teenage years**

The rapid maxillary expansion (RME) type of appliance which produces high forces capable of splitting the mid-palatine suture and bringing about skeletal changes within a

matter of days (0.5mm/ day). The screw is turned twice daily, usually over an active treatment period of 2 weeks The RME screw can be incorporated in two type of appliances

-one, the banded RME, and

-The second kind, the cemented RME

- **As half of the dental expansionis lost, some overexpansion is advisable.**
- **<u>Cross-elastics</u>: from the lingual of upper molars to the buccal of lower molars. This method is also useful when there is true unilateral crossbite.**

After correction of crossbite retention is achived using heavy rectangular archwire

- **In adults bilateral posterior crossbite usually accepted, as a functional problem is rare & partial relapse may result in a unilateral crossbite with displacement..**

- **In all patients whether children or adolescents, the crossbite should be overcorrected so that the palatal cusps of upper teeth occlude on the lingual inclines of buccal cusps of lower molars.**
- **After active treatment the appliance is left passively in place for 3 months.**
- **A removable retainer that covers the palate is needed to prevent relapse for 6 months or more.**

Refrences

-An Introduction to Orthodontic.fourth edition 2013 United Kingdom--Laura Mitchell, MBE Oxford

-CONTEMPORARY ORTHODONTICS , FifTH EDITION 2013--WILLIAM R. PROFFIT, MOSBY

--Textbook of Orthodontics Second Edition: 2007--Gurkeerat Singh, Jaypee New Delhi 110 002, India

--ORTHODONTIC REVIEW, SECOND EDITION 2015--Jeryl D. Sercan Akyalcin -Timo Peltomäki -Kate Litschel, by Mosby, an imprint of Elsevier Inc

Incisal bite

Overbite The overlap of the lower incisors by the upper incisors in the vertical plane.

Complete overbite An overbite in which the lower incisors contact either the upper incisors or the palatal mucosa

Incomplete overbite An overbite in which the lower incisors contact neither the upper incisors nor the palatal mucosa.

Anterior open bite The lower incisors are not overlapped in the vertical plane by the upper incisors and do not occlude with them.

Posterior open bite (POB): when the teeth are in occlusion there is a space between the posterior teeth

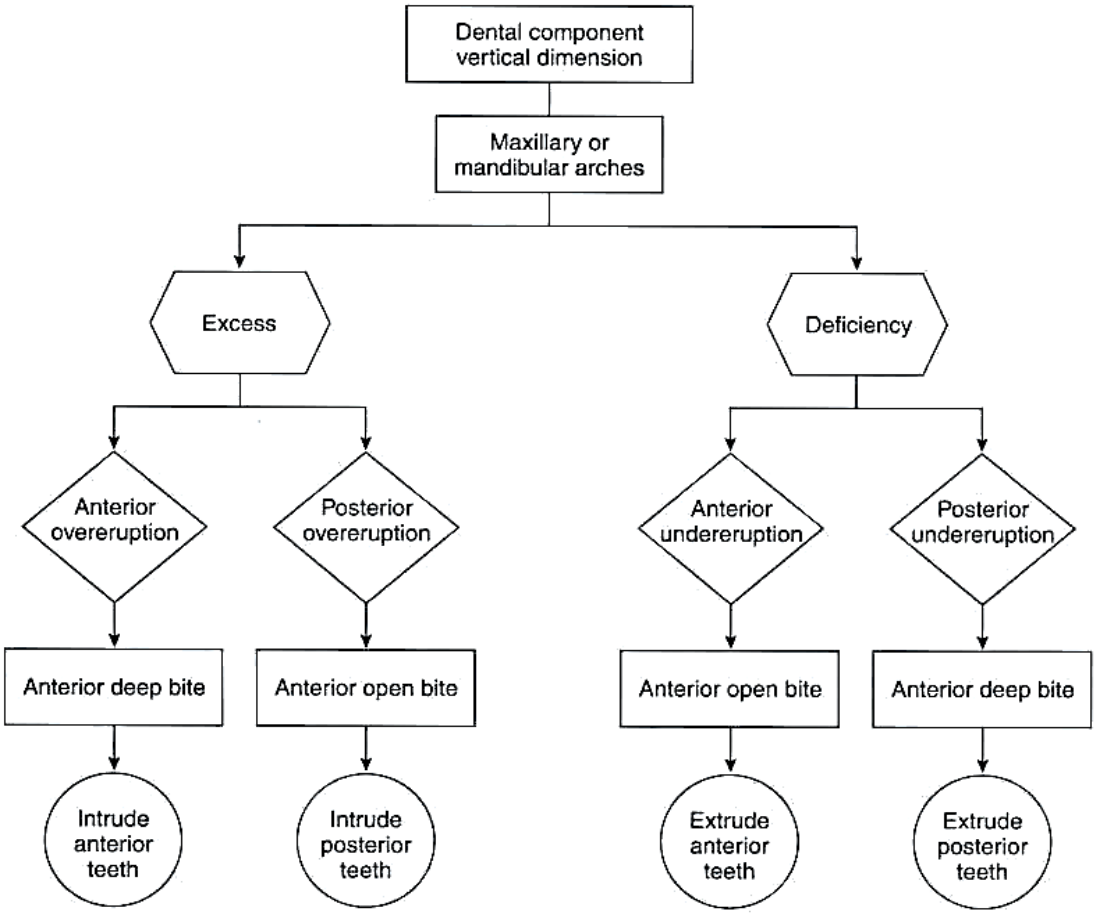

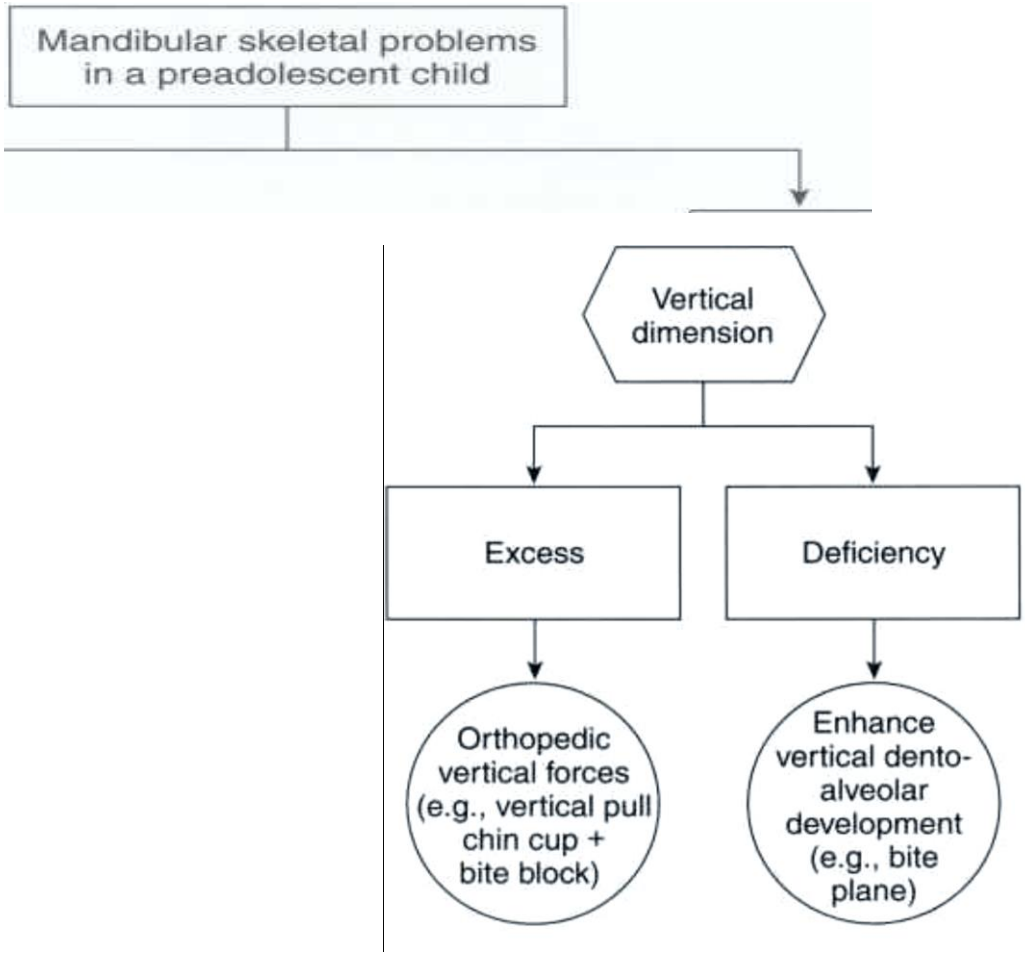
Mandibular skeletal problems in a preadolescent child
Vertical dimension
Excess
Deficiency
Orthopedic vertical forces (e.g., vertical pull chin cup + bite block)
Enhance vertical dento-alveolar development (e.g., bite plane)

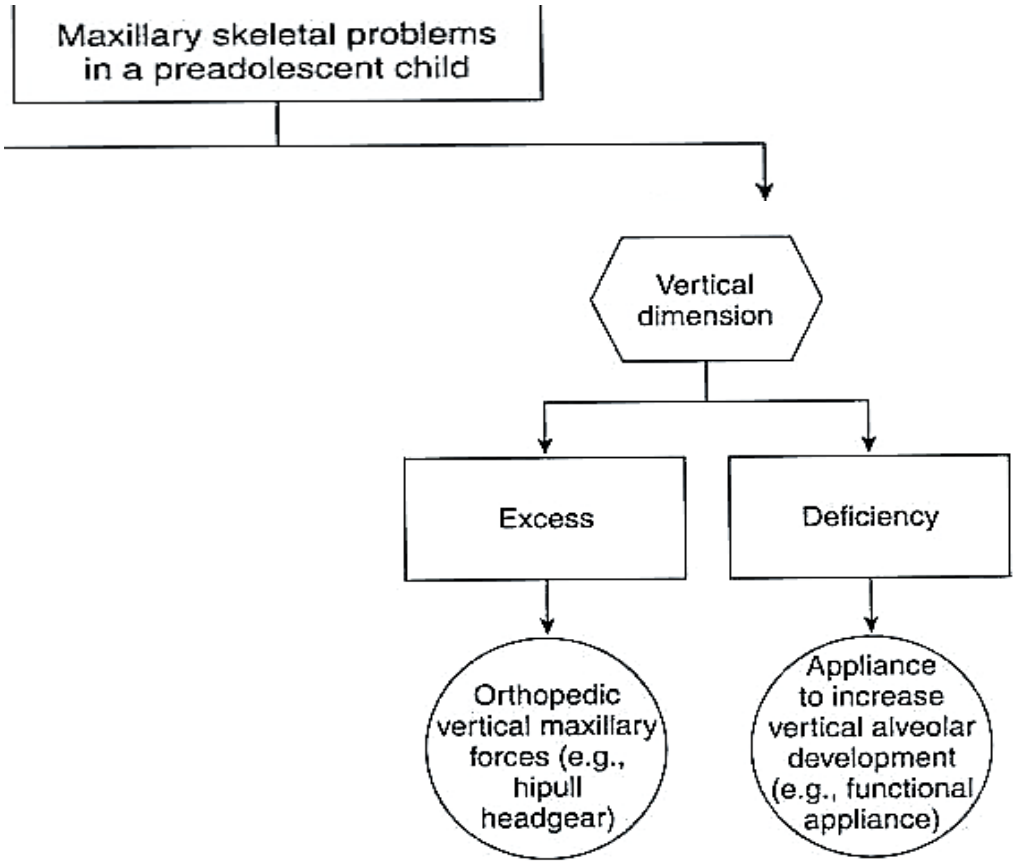
Maxillary skeletal problems in a preadolescent child
Vertical dimension
Excess
Deficiency
Orthopedic vertical maxillary forces (e.g., hipull headgear)
Appliance to increase vertical alveolar development (e.g., functional appliance)

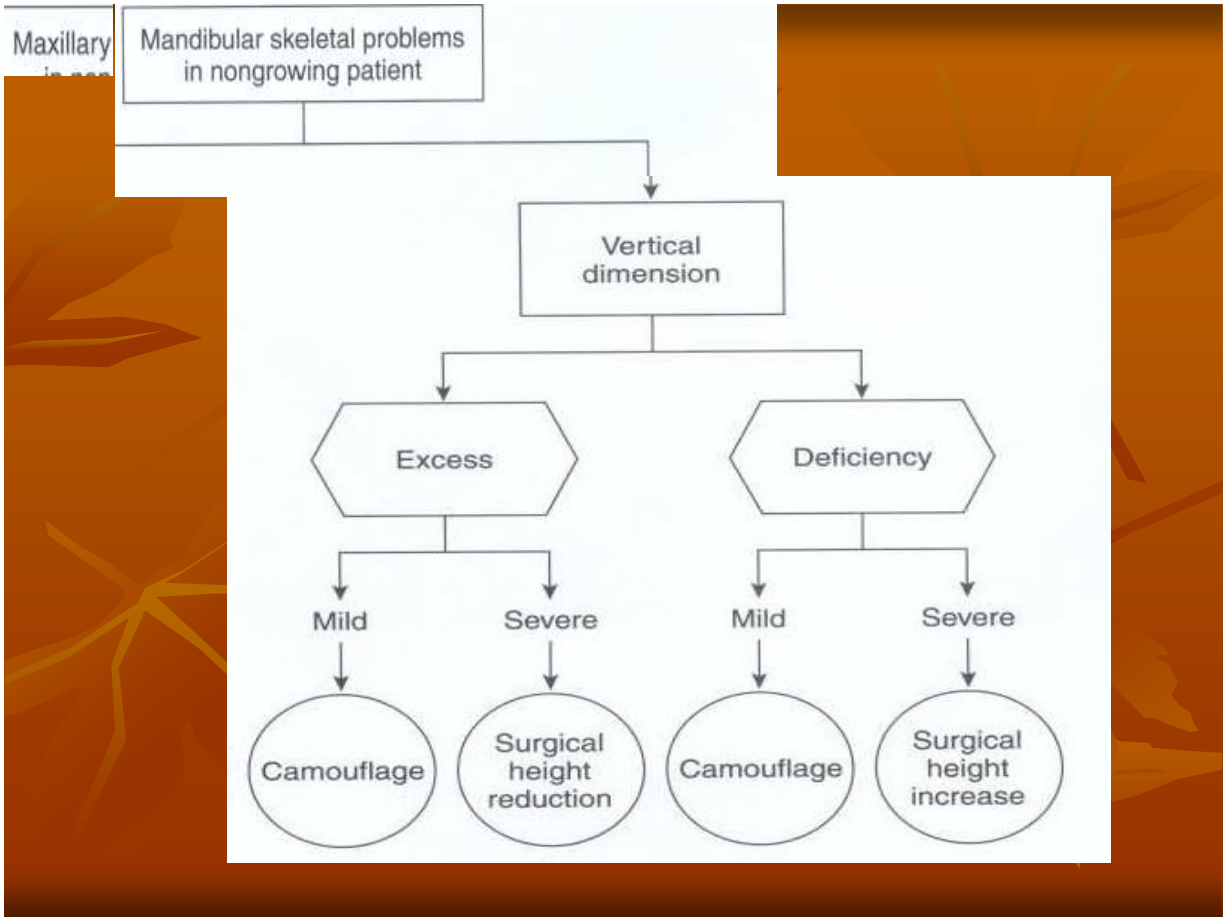

Increase in overbite

- ***Skeletal factors.*** It is often stated that a small lower facial height is associated with a deep overbite. However, this is not a constant relationship and occlusal factors (see below) must also play a part.
- ***Occlusal factors.*** Where there is no incisor contact due to a large overjet (Class II Division 1), the lower incisors will often erupt until they contact the palatal mucosa and the overbite will be deep
- Where the overjet is normal and the incisors are retroclined (Class II Division 2), so that the interincisor angle is increased, the overbite will also be increased

Causes of increased and traumatic overbite

Cause	Aetiology
Skeletal: anteroposterior and vertical	A Class II skeletal pattern in combination with a reduced lower facial height
Growth pattern	An anterior mandibular growth rotation tends to increase overbite
Soft tissues	Effects are via the skeletal pattern—reduced lower facial height leads to a high lower lip line that will retrocline the upper incisors, leading to overbite increase A hyperactive high lower lip in association with a reduced lower facial height leads to bimaxillary retroclination
Dental factors	Absence of a well-defined cingulum stop on the upper incisors leads to continued eruption of the lower incisors, increasing overbite

Approaches to the reduction of overbite

Intrusion of the incisors

- **Actual intrusion of the incisors is difficult to achieve. Fixed appliances are necessary** and the mechanics employed pit intrusion of the incisors against extrusion of the buccal segment teeth; as it is easier to move the molars occlusally than to intrude the incisors into bone, the former tends to predominate. In practice, the effects achieved are relative intrusion, where the incisors are held still while vertical growth of the face occurs around them

Eruption of the molars

- **Use of a flat anterior bite-plane** on an upper removable appliance to free the occlusion of the buccal segment teeth will, if worn conscientiously, limit further occlusal movement of the incisors and allow the lower molars to erupt, thus reducing the overbite. This method requires a growing patient to accommodate the increase in vertical dimension that results, otherwise the molars will reintrude under the forces of occlusion once the appliance is withdrawn

Extrusion of the molars

- As mentioned above, the major effect of attempting intrusion of the incisors is often extrusion of the molars. This may be advantageous in Class II division 2 cases as this type of malocclusion is usually associated with reduced vertical proportions. Again, vertical growth is required if the overbite reduction achieved in this way is to be stable

There are three possible ways to level a lower arch with an excessive curve of Spee:

(l) absolute intrusion;

(2) relative intrusion, achieved by preventing eruption of the incisors while growth provides vertical space into which the posterior teeth erupt; and

(3) extrusion of posterior teeth, which causes the mandible to rotate down and back in the absence of growth.

Note that the difference between (2) and (3) is whether the mandible rotates downward. This is determined by whether the ramus grows longer while the tooth movement is occurring

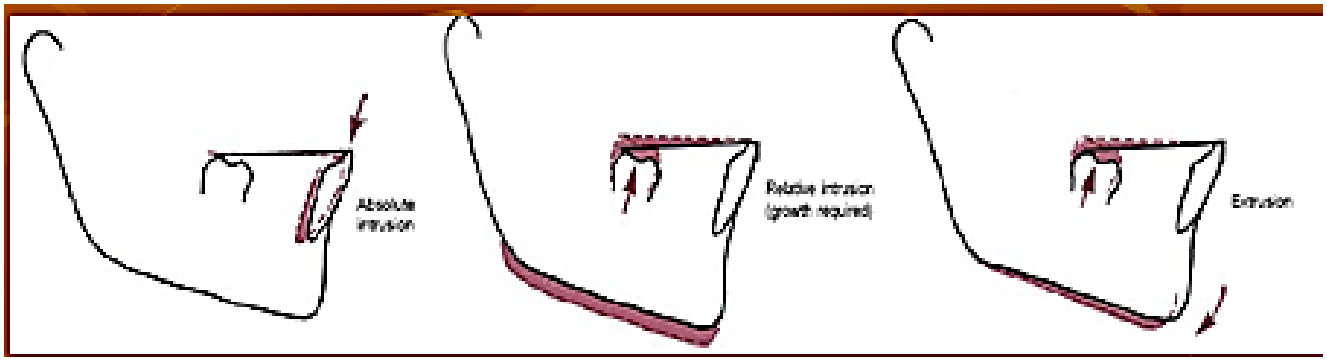

Proclination of the lower incisors

Advancement of the lower labial segment anteriorly will result in a reduction of overbite as the incisors tip labially. This approach should only be carried out by the experienced orthodontist. However, in a few cases where the lower incisors have been trapped behind the upper labial segment by an increased overbite, fitting of an upper bite-plane appliance may allow the lower labial segment to procline spontaneously

Surgery

In adults with a markedly increased overbite and those patients where the underlying skeletal pattern is more markedly Class II, a combination of orthodontics and surgery is required.

The reduction of a deep overbite will <u>be stable only</u> if at the end of treatment the :

- **lower incisors occlude with the palatal surfaces of the upper incisors**,
- **the interincisor angle is within the normal range,**
- **and the teeth are in a position of labiolingual balance**

AETIOLOGY OF ANTERIOR OPEN BITE

- *Skeletal factors*
- *Soft tissue factors*
- *Habits*
- *Mouth breathing*
- Localized failure of development

Skeletal

Individuals with a tendency to **vertical** rather than horizontal facial growth exhibit increased vertical skeletal proportions. Where the **lower face height is increased** there will be an increased inter-occlusal distance between the maxilla and mandible. Although the labial segment teeth appear to be able to compensate for this to a limited extent by further eruption, where the inter-occlusal distance exceeds this compensatory ability an **anterior open bite will result**. If the vertical, downwards, and backwards, pattern of growth continues, the anterior open bite will become more marked.

Lower facial height: the distance from the eyebrow to the base of the nose should equal the distance from the base of the nose to the lowermost point on the chin. If the latter distance is increased, the lower facial height is described as being increased, and vice versa.

- ***Frankfort mandibular planes angle*** (FMPA).: assessment of the FMPA clinically by eye comes with experience, but the neophyte orthodontist may find it helpful to assess this angle by placing one hand level with the Frankfort plane (external auditory meatus to the lower border of the orbital margin) and the other hand level with the

lower border of the mandible. Then in the ‘mind's eye’ extrapolate the planes and assess where they would cross. If the angle between these two planes is around the average **of 28°,** then the lines would intersect approximately at the back of the head. If the FMPA is **increased** the lines would meet before the back of the head, and if it is **reduced** they would **cross beyond**.

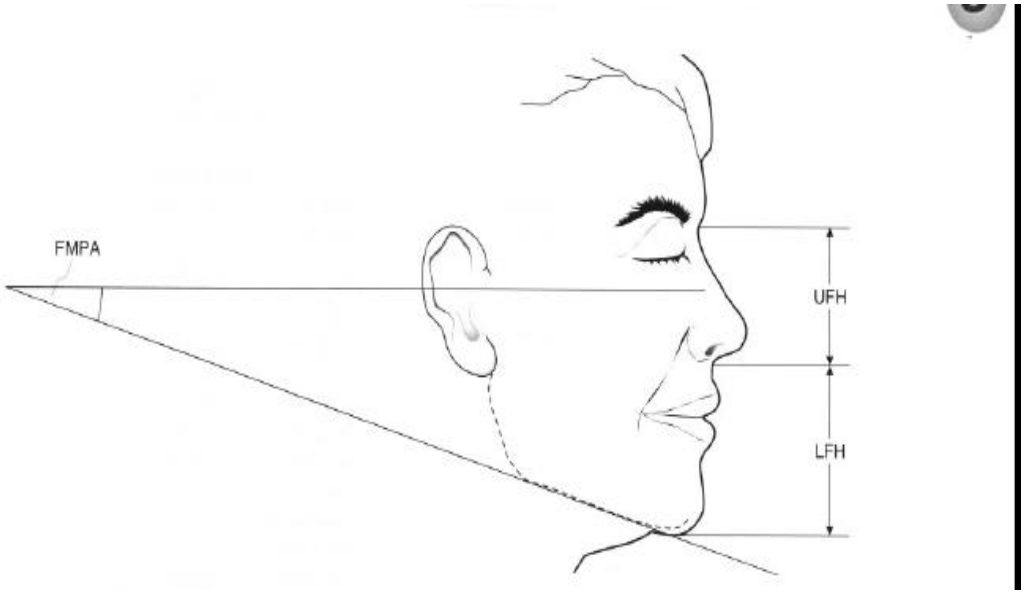

Soft tissue pattern

In order to be able to **swallow** it is necessary to create an anterior oral seal. In younger children the lips are often incompetent and a proportion will achieve an anterior seal by positioning their tongue forward between the anterior teeth during swallowing.

Individuals with increased vertical skeletal proportions have an increased likelihood of **incompetent lips** and may continue to achieve an anterior oral seal in this manner even when the soft tissues have matured *adaptive* tongue behavior

Primary atypical tongue behaviour (endogenous tongue thrust)

- Rarely there is an inborn atypical pattern of neuromuscular activity by which the tongue tip retains a more infantile position, and comes forwards to contact the lips during swallowing (an *endogenous* tongue thrust). This can produce both an increase in overjet and a reduction in overbite

Habits

- The effects of a habit depend upon its **duration** and intensity. The persistence of pernicious habit can lead to the malocclusion acquiring a skeletal component .If a persistent digit-sucking habit continues into the mixed and permanent dentitions, this can result in an anterior open bite due to restriction of development of the incisors by the finger or thumb

- Characteristically, the anterior open bite produced is **asymmetrical** (unless the patient sucks two fingers) and it is often associated with a posterior crossbite. Constriction of the upper arch is believed to be caused by cheek pressure and a low tongue position

Mouth breathing

It has been suggested that the open-mouth posture adopted by individuals who habitually mouthbreathe, either due to nasal obstruction or habit, results in **over development of the buccal segment teeth**. This leads to an increase in the height of the lower third of the face and consequently a greater incidence of anterior open bite.

- **Localized failure of development**

This is seen in patients with a cleft of the lip and alveolus, although rarely it may occur for no apparent reason

Features of dental anterior open bites

❖ **Intraoral features:**

1. Open bite limited to the anterior segment, often asymmetrical.
2. Proclincd maxillary and/or mandibular incisors.
3. Spacing between maxiliary and/or mandibular anteriors.
4. Narrow maxillary arch is a possibility.
5. "Fish mouth" appcarrmcc.

❖ **Extraora! features:**

No unusual features.

Features of skeletal anterior open bites

❖ **Extraoral features:**

1. Long face due to increased lower anterior face height

2. Incompetent lips

3. An increased mandibular plane angle

4. An increased gonial angle

5. Marked antegonial notch

6. A short mandible is a possibility

7. Maxillary base may be more inferiorly placed (vertical maxillary excess)

8. The angle formed by the mandibular and maxillary planes is also increased

❖ **Intraoral features:**

1. **Mild crowding with upright incisors**
2. **Gingival hypertrophy**
3. **Maxillary, occlusal and palatal planes tilt upwards**
4. **Mandibular occlusal plane canted downwards**

Management of an anterior open bite due to purely a digit-sucking habit can be straightforward, but where the skeletal pattern, growth, and/or soft tissue environment are unfavourable, correction without resort to orthognathic surgery may not be possible.

- In the mixed dentition, a digit-sucking habit that has resulted in an anterior open bite should be gently discouraged. If a child is keen to stop, a removable appliance can be fitted to act as a reminder. However, if the child derives support from his habit, forcing him to wear an appliance to discourage it is unlikely to be successful.
- Although a number of barbaric designs have been described (involving wire projections for example), a simple plate with a long labial bow for anterior retention will usually suffice if a habit-breaker is indicated.

- After fitting, the acrylic behind the upper incisors should be trimmed to allow any spontaneous alignment.
- A period of observation may be helpful in the management of patients with an anterior open bite which is not associated with a digit-sucking habit.
- In some cases an anterior open bite may reduce spontaneously, *possibly because of* maturation of the soft tissues and improved lip competence, or favourable growth

Approaches to the management of anterior open bite

There are three possible approaches to management

1-Acceptance of the anterior open bite

2-Orthodontic correction of the anterior open bite.

3-Surgery

Acceptance of the anterior open bite

This approach can be considered in the following situations (particularly if the AOB does not present a problem to the patient):

- mild cases;
- where the soft tissue environment is not favourable, for example where the lips are markedly incompetent and/or an endogenous tongue thrust is suspected;
- in more marked malocclusions where the patient is not motivated towards surgery.

Orthodontic correction of the anterior open bite

- If growth and the soft tissue environment are favourable, an orthodontic solution to the anterior open bite can be considered.

A careful assessment should be carried out, including

- the anteroposterior and vertical skeletal pattern,
- the feasibility of the tooth movements required,
- and post-treatment stability

Extrusion of the incisors to close an anterior open bite is inadvisable, as the condition will relapse once the appliances are removed. Rather,

treatment should aim to try and intrude the molars, or at least control their vertical development.

Intrusion of the molars can be attempted with high-pull headgear and/or by using buccal capping on a removable appliance

- A chin cup with a vertical pull head cap may be used for the correction of anterior open bites in the pre-adolescent age group.
- In the milder malocclusions the use of high-pull headgear during conventional treatment may suffice.

In cases with a more marked anterior open bite associated with a Class II skeletal pattern, a removable appliance or a **functional appliance incorporating buccal blocks and high-pull headgear** can be used to try to restrain vertical maxillary growth. In order to achieve true growth modification it is necessary to apply an intrusive force to the maxilla for ***at least 14–16 hours*** per day during the pubertal growth spurt, ***continuing until growth is complete***

Surgery

- This option can be considered **once growth is complete** for severe problems with a skeletal aetiology and/or where dental compensation will not give an aesthetic or stable result. In some patients an anterior open bite is associated with a **'gummy' smile** which can be difficult to reduce by orthodontics alone necessitating a **surgical approach**

Refrences

-An Introduction to Orthodontic.fourth edition 2013 United Kingdom--Laura Mitchell, MBE Oxford

-CONTEMPORARY ORTHODONTICS , FifTH EDITION 2013--WILLIAM R. PROFFIT, MOSBY

--Textbook of Orthodontics Second Edition: 2007--Gurkeerat Singh, Jaypee New Delhi 110 002, India

--ORTHODONTIC REVIEW, SECOND EDITION 2015--Jeryl D. Sercan Akyalcin -Timo Peltomäki -Kate Litschel, by Mosby, an imprint of Elsevier Inc

ORTHODONTIC DIAGNOSIS

- The primary task for the clinician is to identify the problem and find its etiology .
- Once this is done , and only then can a treatment plane be formulated.

Diagnosis involve the development of a comprehensive and concise data base of information ,sufficient to understand the patient problem as well as answer question arising in the treating clinician mind.

Orthodontic diagnosis :-

- deals with recognition of the various characteristics of the malocclusion and dentofacial deformity.
- should be based on scientific knowledge combined at times with clinical experience and common sense.
- design a treatment strategy based on the specific needs and desires of the individual;
- present the treatment strategy to the patient in such a way that the patient fully understands his/her decision.

The data base is derived from diagnostic aids

They are of two types –

a. ***Essential diagnostic aids*** -
   - *i. Case history*
   - *ii. Clinical examination*
   - *iii. Study models*
   - *iv. Certain radiographs –*
     - *Panoramic radiograph*
   - *v. Facial photographs*

b. ***Supplemental diagnostic aids*** –
   - *i. Specialized radiographs*
   - *ii. Electro myographic examination of muscle activity*
   - *iii. Hand – wrist radiograph*
   - *iv. Endocrine tests*

- **CASE HISTORY:-**

- **Personal details** –

NAME –

Communication

Identification

Psychological benefits

It makes the patients more comfortable when he is addressed by his first name and arouses a feeling of familiarity, which has a positive psychological effect on the patient

Age and Date of Birth –

The chronologic age of the patient helps in:-

- Diagnosis and treatment planning
- Growth modification procedures
- Surgical resective procedures

The age of the patient also dictates the use of certain treatment protocols-for example, surgical correction might be advocated following cessation of growth whereas the same malocclusion might be treated using functional appliances if the patient has a potential to grow.

- **. SEX** – Treatment planning

e. g. the timing of growth events such as growth spurts are different in males and females, Females precede males in onset of growth spurts, puberty and termination of growth

- . **Address and occupation –**

Evaluation of socio – economic status

In selection of an appropriate appliance

- **Race :** negroid race usually obtain an anterior diversion of the face with bimaxillary alveolodental protrusion

- **Referred by :** can give us a good impression about the patient co-operation
  - **CHIEF COMPLAINT The patient's chief complaint should be recorded in his/her own words.**

▶ **This helps the clinician in identifying the priorities and desires of the patient.**

▶ **There are three major reasons for patient concern about the alignment and occlusion of the teeth:**

- impaired dento-facial esthetics that can lead to psychosocial problems,

- &a desire to enhance dento-facial esthetics and thereby the quality of life.

- impaired function,

- **MEDICAL HISTORY :-**

In obtaining the medical history, the orthodontist or assistant must always ask a few important questions, as

the last time a physician was seen, any hospitalizations,

any medications currently being taken.

information regarding allergies, especially latex or nickel sensitivity;

history of blood transfusions; and heart problems such as mitral valve prolapse or rheumatic fever .

- **DENTAL HISTORY :-**

The dental history of the patient should include ,

age of eruption of the deciduous and permanent teeth,

history of extraction, decay, restorations and

history of trauma to the dentition.

- **PRENATAL HISTORY**-

it include information on the condition of the mother during pregnancy and the type of delivery.

- Forceps delivery predispose to TMJ injuries that can result mandibular growth retardation
- The use of drugs , or even excess use of certain vitamins or affectation with some infection during pregnancy like german measles can results in congenital deformities of child.

POST NATAL HISTORY -it includes information on the type of feeding, presence of habits especially digit sucking and tongue thrust.

FAMILY HISTORY- class II,classIII malocclusions and congenital conditions such as clefts of lip & palate are inherited.

Family history should record details of mal-occlusion existing in other members of the family.

GENERAL EXAMIATION

- Height and weight-they provide clue to the physical growth and maturation of the patient.
- Gait-(way a person walks) abnormalities of gait are usually associated with neuromuscular disorders that may have a dental correlation.

- Posture-(way a person stands)abnormal postures can predispose to malocclusion due to alteration in maxillo-mandibular relationship.

SHELDEON CLASSIFICATION OF BODY BUILD

- A)ECTOMORPHIC- tall and thin physique
- B) MESOMORPHIC- average physique
- C)ENDOMORPHIC- short and obese physique

EXTRA ORAL EXAMINATION

SHAPE OF THE HEAD:

- A)MESOCEPHALIC-average shape of the head. posses normal dental arches
- B)DOLICOCEPHALIC-long and narrow head . They have narrow dental arches
- C)BRACHYCEPHALIC-broad and short head. broad dental arches

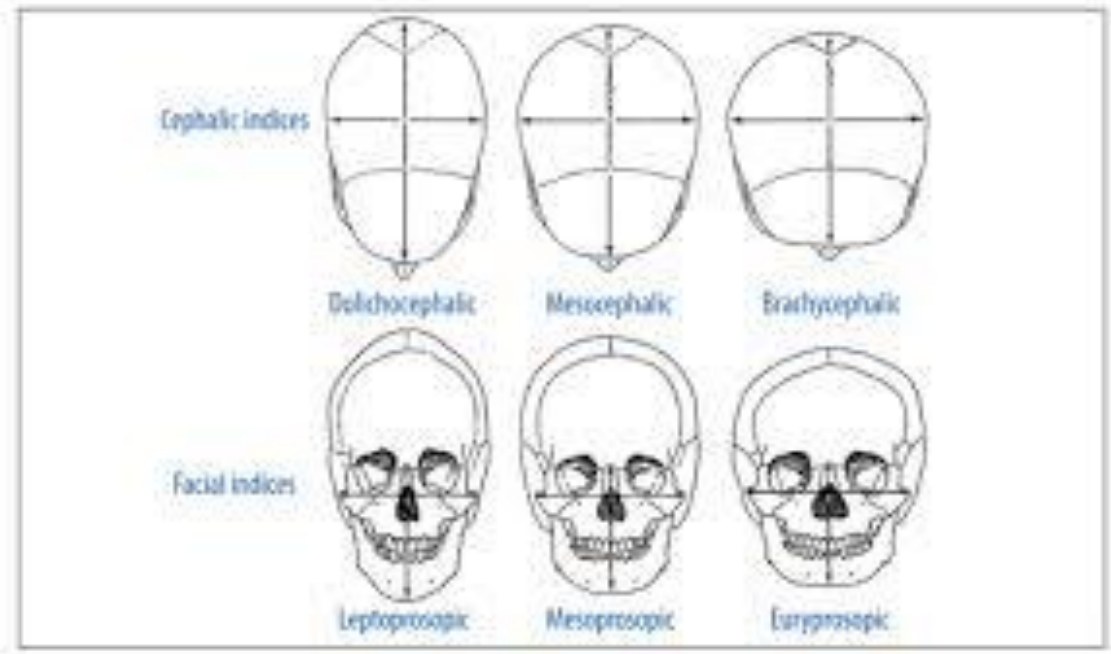

FACIAL FORM

- A)MESOPROSOPIC-average or normal face form
- B)EURYPROSOPIC-face is broad and short
- C)LEPTOPROSOPIC-long and narrow face form

Facial index

- The shape of the face is assessed by the morphologic facial index which was given by Martin and Saller (1957) as:

Morphologic facial height (distance between nasion and gnathion)

I = ----------

Bizygomatic width (distance between the zygoma points)

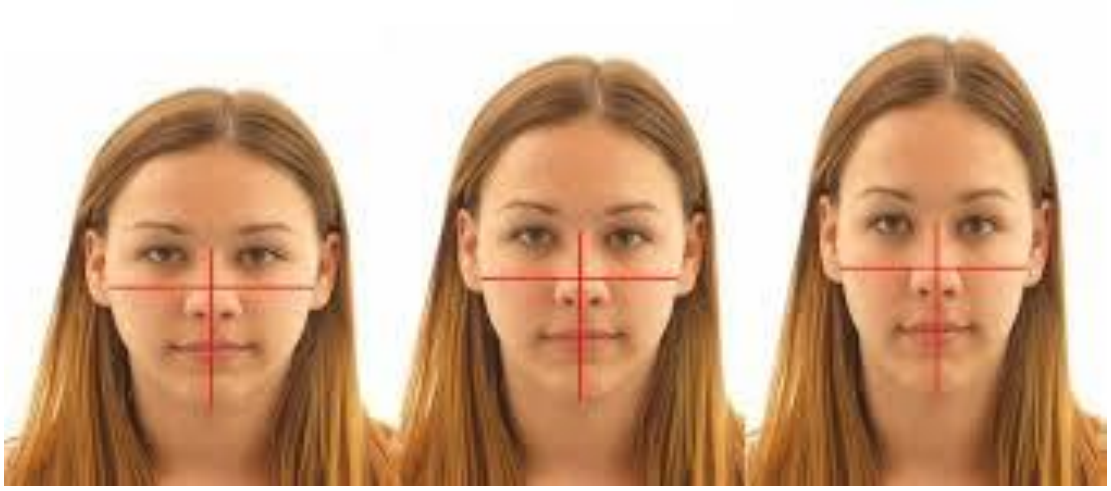

The type of facial morphology has a certain relationship to the shape of the dental arch, e.g. :- euryprosopic face types have broad, square arches; border line crowding in such cases should be treated by expansion.

- On the other hand, leptoprosopic face types often have narrow apical basel arches. Therefore, extraction is preferred over expansion.

FACIAL SYMMETRY

- The patient's facial symmetry is examined to determine disproportions of the face in transverse and vertical planes. Gross facial asymmetry can occur as a result of:
- A. congenital defects
- B.hemi-facial atrophy/hypertrophy
- C.unilateral condylar ankylosis and
- D.unilatera hyperplasia

The role of fifth

Facial proportions and symmetry in the frontal plane. An ideally proportional face can be divided into central , medial ,and lateral equal fifths. The separation of the eyes and the width of the eyes, which should be equal ,determine the central and medial fifths. The nose and chin should be cantered within the central fifth, with the width of the nose the same as or slightly wider than the central fifth. The inter – pupillary distance (dotted lines) should equal the width of the mouth

Vertical facial proportions in the frontal and lateral views are best evaluated in the context of the facial thirds, which are equal in height in well-proportioned faces. In modern Caucasians, the lower facial third often is slightly longer than the central third. The lower third has thirds : the mouth should be one-third of the way between the base of the nose and the chin.

FACIAL PROFILE

- **The facial profile is examined by viewing the patient from the side. the facial profile helps in diagnosing the gross deviation of maxillo-mandibular relationship. the profile is assessed by joining the <u>following two reference lines:-</u>**

1. **A line joining the forehead and the soft tissue point A(deepest point in curvature of upper lip)**
2. **A line joining point A and the soft tissue pogonion(most anterior part of the chin)**

- **STRAIGHT / orthognathic PROFILE -the two lines form nearly straight line.**
- **CONVEX PROFILE -the two lines form an angle with concavity facing the tissue. (This kind of profile occurs as a result of prognathic maxilla retrognathic mandible as seen in Class II div 1 patients)**
- **COCAVE PROFILE -the two reference lines form an angle with convexity towards tissue. (This type of profile is associated with a prognathic mandible or retrognathic maxilla as in Class Ill patients)**



FACIAL DIVERGENCE

Facial divergence is defined as anterior or posterior inclination of the lower face relative to the forehead.



- **ANTERIOR DIVERGENT-a line drawn between the forehead and the chin is inclined anteriorly towards the chin..**

POSTERIOR DIVERGENT

- **A line drawn between the forehead and chin slants posteriorly towards chin.**

STRAIGHT/ORTHOGNATHIC

- **The line between the forehead and the chin is straight or perpendicular to the floor.**
- **The facial divergence is to a large extend influenced by patient's ethnic and racial background.**

ASSESSMENT OF ANTERO-POSTERIOR JAW RELATIONSHIP

- **It can be assessed clinically.**

- **Ideally maxillary skeletal base is 2-3 mm ahead of the mandibular skeletal base when the teeth are in occlusion.**
- **Estimation is done by placement of index and middle fingers at the soft tissue point A and point B respectively.**
- **In skeletal CLASS II PATIENTS, the index finger is anterior to middle finger or the hand points upwards.**
- **In a skeletal CLASS III patient, the middle finger is ahead of the forefinger or the hand points downwards.**
- **In a patient with CLASS I skeletal pattern the hand is at an even level.**

ASSESSMENT OF VERTICAL SKELETAL RELATIONSHIP

- **The vertical skeletal relationship assessed by studying the angle formed between the lower border of the mandible and the Frankfort horizontal plane (a line between the most superior point of external auditory meatus and inferior border of orbit)**
- **Normally the two planes intersects near the occipital region.**
- **In case the two planes meets beyond the occipital region, it indicates a low angle case or a horizontal growing face.**
- **If two planes meet anterior to occipital region it indicates a high angle case or a vertical growing face.**
- **A normal vertical relationship is one where the distance between the glabella and subnasale is equal to the distance from the subnasale to the under side of the chin.**
- **Reduced lower facial height is associated with deep bites while increased lower facial height is seen in anterior open bites.**

Examination of the Soft Tissues

- **Extraoral**

1. Forehead **For a face to be harmonious, the height of the forehead (distance from hairline to glabella) should be as long as the mid-third (glabella-to-subnasale) and the lower third (subnasale-to-menton), i.e. each of these is one-third the total face height**

2. Nose Size, shape and position of the nose determines the esthetic appearance of the face

EXAMINATION OF LIPS

- **The upper lip covers the entire labial surface of upper anteriors except the incisal 2-3 mm**
- **The lower lip covers the entire labial surface of lower anteriors and 2-3 mm of incisal edge of upper anteriors.**

CLASSIFICATION OF LIPS

- **COMPETENT LIP-THE LIPS ARE IN SLIGHT CONTACT WHEN MUSCULATURE IS RELAXED.**
- **INCOMPETENT LIPS-they are morphologically short lips which do not form a lip seal in a relaxed state.**
- **The lip seal can only be achieved by active contraction of perioral and mentalis muscle.**
- **POTENTIALLY INCOMPETENT LIP-they are normal lips that fails to form a lip seal due to proclained upper incisor.**

EVERTED LIP-they are hypertrophied lips with weak muscular tonicity.

EXAMINATION OF CHIN

- **MENTOLABIAL SULCUS-concavity seen below the lower lip. Deep mentolabial sulcus is seen in CLASS11,DIVISON 1 malocclusion.**
- **CHIN POSITION AND PROMINENCE-prominent chin is usually associated with class 111 malocclusion.**
- **NASOLABIAL ANGLE :-**

This is the angle formed between a tangent to the lower

border of the nose and a line joining the subnasale with

the tip of the upper lip (labrale superius)

- **This angle is normally 100◦-110◦ .**
- **It reduces in patients having proclined upper anteriors or prognathic maxilla.**
- **It increases in patients with retrognathic maxilla or retroclined maxillary anteriors.**

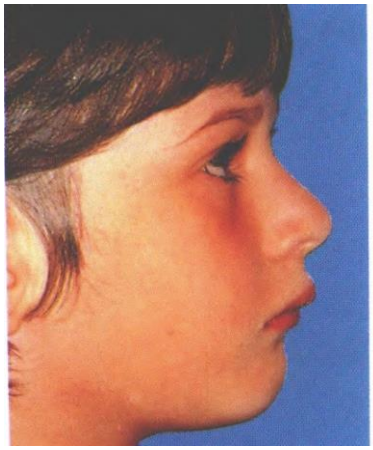

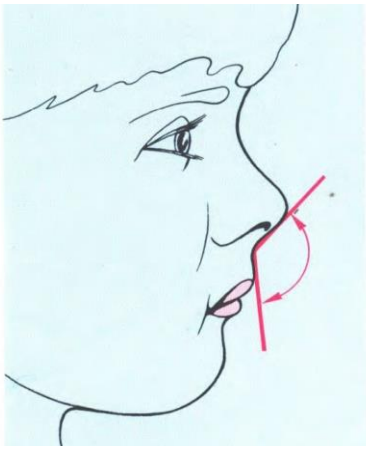

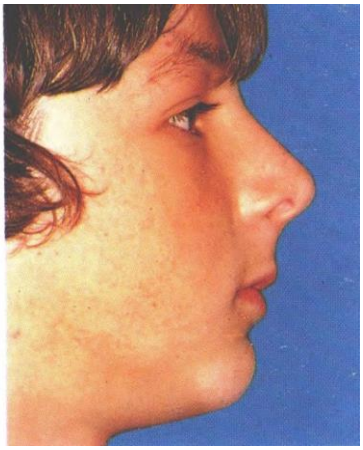

Refrences

-An Introduction to Orthodontic.fourth edition 2013 United Kingdom--Laura Mitchell, MBE Oxford

-CONTEMPORARY ORTHODONTICS , FifTH EDITION 2013--WILLIAM R. PROFFIT, MOSBY

--Textbook of Orthodontics Second Edition: 2007--Gurkeerat Singh, Jaypee New Delhi 110 002, India

--ORTHODONTIC REVIEW, SECOND EDITION 2015--Jeryl D. Sercan Akyalcin -Timo Peltomäki -Kate Litschel, by Mosby, an imprint of Elsevier Inc